

**ELECTROGRAPHIC PATTERNS OF MAGNESIUM DEPLETION  
APPEARING IN ALCHOLIC HEART DISEASE**

Mildred S. Seelig



Reprinted from  
**ANNALS OF THE NEW YORK ACADEMY OF SCIENCES**  
Volume 162, Article 2, Pages 906-917  
August 15, 1969

#### SECTION IV. ROLE OF CHRONIC ALCOHOLISM IN MAGNESIUM DEFICIENCY

##### ELECTROGRAPHIC PATTERNS\* OF MAGNESIUM DEPLETION APPEARING IN ALCOHOLIC HEART DISEASE

Mildred S. Seelig†

*Pharmacology Department, New York Medical College, New York, N. Y.;*  
*Pediatric Department, Maimonides Hospital, Brooklyn, N. Y.*

Most clinical studies of the effect of magnesium loss in alcoholism have emphasized the neurological manifestations. Comparison of the cardiac findings in experimental magnesium deficiency with those seen in alcoholic heart disease, points to magnesium depletion as a pathogenic factor, also, in this disease. Since chronic alcoholism causes multiple nutritional deficiencies, the syndrome does not precisely mimic pure experimental magnesium deficiency, but there are striking similarities in the two conditions. Although there is difference of opinion as to the degree of magnesium loss, even as expressed during this conference, alcoholism has been shown to cause, not only hypomagnesemia, but also decreased muscle magnesium.<sup>1-6</sup> Because experimental dietary magnesium depletion has caused myocardial lesions,<sup>7-16</sup> and magnesium (plus potassium) salts have been shown to have protective and even therapeutic value against myocardial damage in a number of diverse animal experiments<sup>9-11,17-23</sup> and in clinical cardiovascular disease,<sup>22,24-39</sup> the role of magnesium in the etiology and possibly in the treatment of this disease should be considered.

It is possible that careful study of the electrocardiogram may provide some clues as to changes that may be attributed to magnesium loss in alcoholic heart disease. In evaluating electrocardiographic changes, it is necessary to consider the influence of magnesium loss on potassium and calcium, alterations in levels of which profoundly affect the ECG.<sup>40-43</sup> Magnesium-deficient animals<sup>12,13,44-48</sup> and human subjects<sup>49-52</sup> commonly show both serum and cellular losses of potassium. The degree of loss from each compartment probably is related to the extent and duration of the magnesium deficiency, as well as to the dietary intake of potassium. Hypercalcemia has been seen in rats with hypomagnesemia.<sup>45,53</sup> Hypocalcemia has been seen in magnesium-deficient calves,<sup>16,54</sup> and in human subjects,<sup>52</sup> particularly where malabsorption is a contributing factor.<sup>55-58</sup> Characteristic of animals with magnesium depletion is an increase in cardiovascular calcium deposition.<sup>7,8,12,14-16,19</sup>

To ascertain whether electrocardiographic changes of magnesium deficiency are due to secondary alterations in potassium, Vitale and his coworkers<sup>12,13,59</sup> and Ono<sup>60</sup> have studied the electrocardiograms of magnesium-deficient dogs with normal and low serum levels (FIGURE 1). Animals with moderately severe magnesium deficiency and with essentially normal serum potassium showed slightly widened QRS, peaked T waves, and sometimes slightly depressed ST segments—changes that resemble, in part, those of both hyperkalemia and hypercalcemia. (See FIGURE 2.) The hypomagnesemia tracing has the widened QRS seen in hyperkalemia, and a peaked T wave. The T wave is somewhat broader

\* Illustrations of electrocardiograms (ECG's) are schematic, based on appearance of Lead II, as altered in the conditions discussed.

† Present address: Schering Corporation, Bloomfield, N. J.

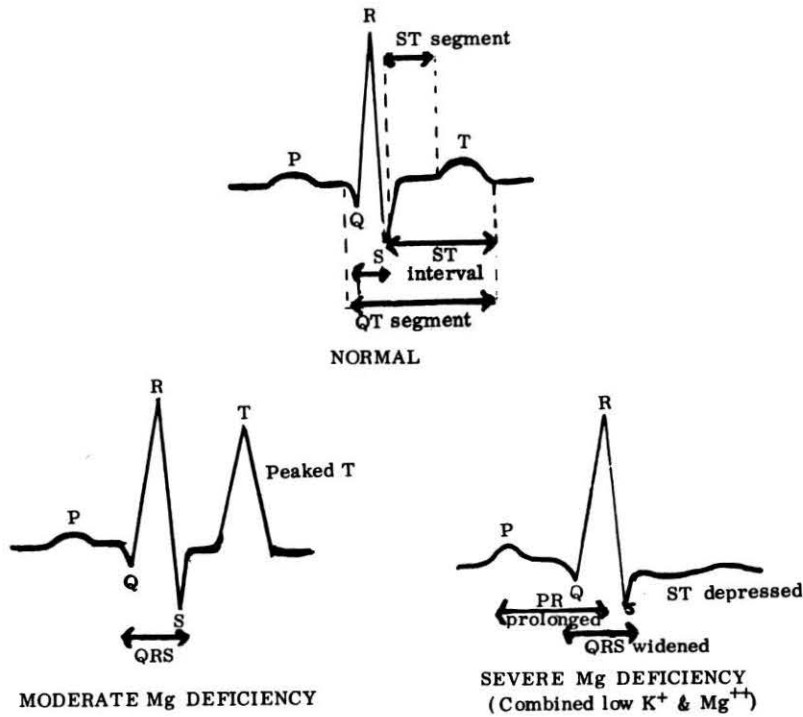


FIGURE 1. Electrocardiograms of magnesium deficiency compared with normal.

than that seen in hyperkalemia, resembling somewhat more that seen in hypercalcemia. The hypercalcemic tracing, however, has a shortened QT. Seta and colleagues<sup>59</sup> attributed the similarity of this hypomagnesemia tracing to that of hyperkalemia in dogs with normal serum potassium to a loss of potassium from the myocardial cells, with a resultant relative hyperkalemia. Syllm-Rapoport,<sup>61</sup> who did not determine serum calcium or potassium levels, postulated that the similarity of the Mg-deficient ECG to that of hypercalcemia, might be explained by the myocardial calcification seen in his magnesium-deficient dogs.

In animals with dietary deficiencies of both magnesium and potassium and with low serum levels of both cations (a condition that obtains, also, late in the course of magnesium-depletion studies in dogs<sup>59-62</sup> and rats<sup>14</sup>), the ECG resembles that of both hypocalcemia and hypokalemia (FIGURE 3). There is prolongation of the PR and QRS segments which, although the hypomagnesemia tracing lacks the prominent U wave of hypokalemia, may be likened either to the prolongation of the QU (with the flattened or inverted T wave of hypokalemia) or to the prolongation of the QT of the hypocalcemia tracing. The ECG of advanced magnesium-depletion also exhibits a flattened or depressed ST segment, such as is seen in tracings from patients or animals with hypokalemia, hypocalcemia, or a combination of both.<sup>41-43</sup>

In the early studies, reported by Kruse<sup>63</sup> and Greenberg<sup>64</sup> and their coworkers, in which acute magnesium depletion was rapidly induced by diets that were deficient also in vitamin B<sub>6</sub>, sinus tachycardia and arrhythmias developed, as did

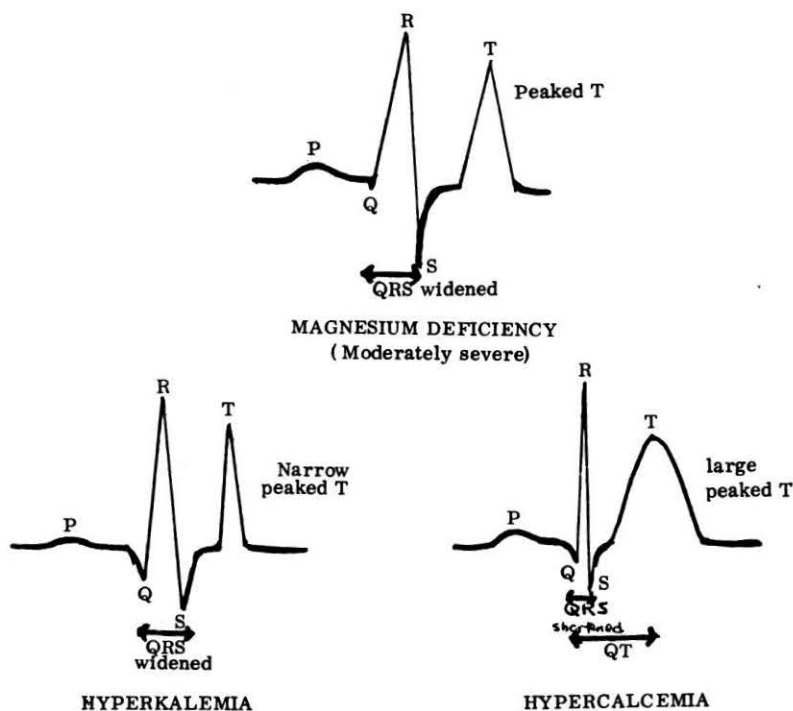


FIGURE 2. Electrocardiogram of moderately severe magnesium deficiency compared with hyperkalemia and hypercalcemia.

the convulsions by which these studies are more commonly remembered. Tachycardia and extra-systoles or premature beats have also been reported in the more recent longer-term studies of moderately severe, essentially pure magnesium dietary deficiency in rats, dogs and pigs.<sup>12,14,59-62,65</sup> Later in the course of severe magnesium deficiency, bradycardia, with missed beats, has been reported in rats, pigs, and monkeys.<sup>13,14,63-65</sup> In studies with rats,<sup>14,63</sup> sino-auricular block has been seen.

Tachycardia and electrocardiographic changes resembling those of hypokalemia or with only primary ST changes, have been commented on or illustrated in a few of the early studies of magnesium losses in acute alcoholism reported by Flink and collaborators<sup>66,67</sup> and by Smith and Hammarsten.<sup>68</sup> Reversion of the waves to normal occurred only after magnesium therapy. Clinical reports, primarily of heart disease in chronic alcoholism, include mention of tachycardia, premature ventricular systoles, and often atrial fibrillation, as characteristic of this disease.<sup>69-73</sup> Reported electrocardiographic changes have included prolonged P-R intervals, ST segment and T wave abnormalities, including prominent, peaked, and notched T waves.<sup>69-72</sup> (See FIGURE 4). The schematic tracings at the top of FIGURE 4 depict patterns during acute manifestations of chronic alcoholic heart disease. The one at the bottom, taken during recovery phases, resembles somewhat the tracings seen in moderately severe experimental magnesium deficiency.

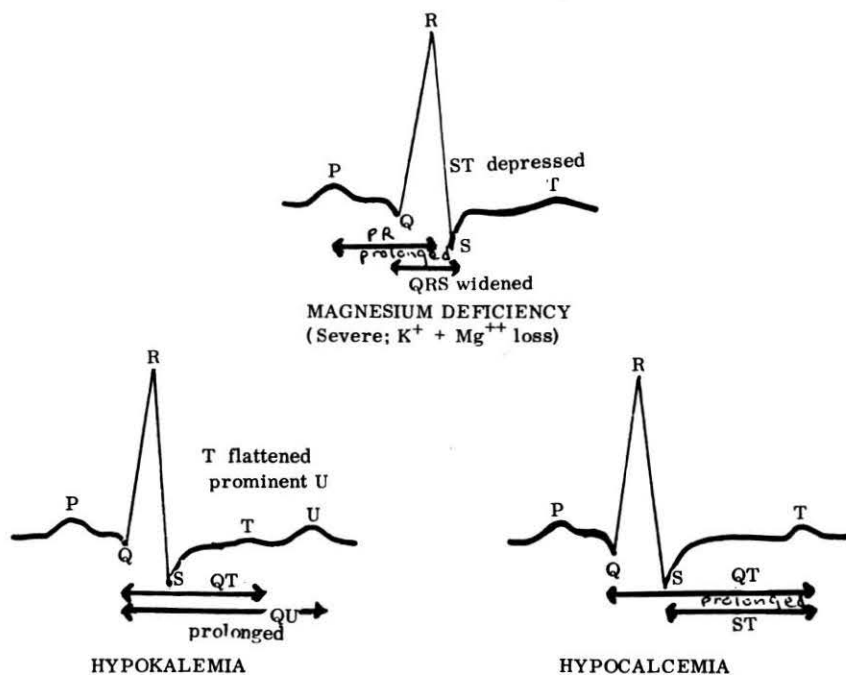


FIGURE 3. Electrocardiogram of severe magnesium deficiency or combined K<sup>+</sup> and Mg<sup>++</sup> deficiency compared with hypokalemia and hypocalcemia.

Because of the variations seen in the ECG's of alcoholic heart disease, Brigden and Robinson<sup>69</sup> have advised against relying too heavily on the specific tracing to indicate the extent of heart damage. They pointed out that the site of the myocardial lesion may influence conduction out of proportion to the absolute size of the lesion, and they commented on the similarities seen in hearts examined at autopsy (patchy focal myocardial necrosis) and in those from magnesium- and/or potassium-depleted animals. Alexander,<sup>70</sup> who analyzed 100 cases of idiopathic heart disease with special reference to alcoholism, found that, in addition to electrocardiographic changes that were primarily in the S-T area, sinus tachycardia, delayed atrioventricular and intraventricular conduction, and bundle branch block were also common. He correlated the changes with hypomagnesemia, as well as with probable thiamine deficiency, to which has been attributed tachycardia, and T wave changes in dogs,<sup>74</sup> and with patchy myocardial necrosis in rats, dogs, and monkeys.<sup>74-76</sup>

One must be careful, in interpreting early B<sub>1</sub>-deficiency experiments, to take into account the likelihood that the diets then used were likely to be deficient in more than just thiamine. For example, the electrocardiographic response of a severely B<sub>1</sub>-depleted dog to intravenous B<sub>1</sub> resulted in a change from a pattern resembling that of advanced magnesium-deficiency to one bearing a resemblance to that seen in moderately magnesium-deficient animals<sup>74</sup> (FIGURE 5). Zieve's<sup>77</sup> study, included in this monograph, sheds light on this observation by showing the interrelationship of magnesium- and thiamine-deficiency. It may be that interference by magnesium-deficiency with the response to thiamine-repletion

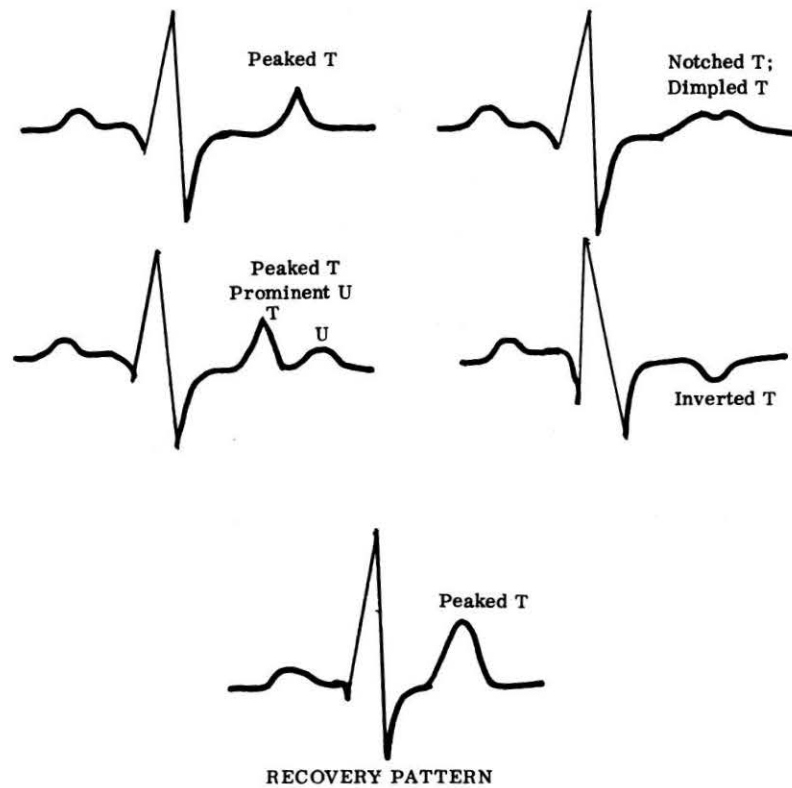


FIGURE 4. Electrocardiograms of chronic alcoholism.

in double deficiency, may be responsible for the failure to achieve a favorable response to thiamine in many chronic alcoholics with beriberi.

Burch and Walsh<sup>71</sup> also correlated the T wave changes of alcoholic heart disease with those of beriberi and touched in passing on a possible relationship with pyridoxine-deficiency. Relevant here is the observation by Aikawa<sup>78</sup> that pyridoxine deficiency in rabbits is associated with decreased  $Mg^{28}$  tissue uptake, and that pyridoxine administration increases the cardiac  $Mg^{28}$  activity. Seronde<sup>79</sup> has shown degenerative myocardial lesions in  $B_6$ -deficient rats.

The pathological findings of alcoholic heart disease have also been compared<sup>71</sup>




FIGURE 5. Electrocardiograms of thiamine-deficient dog.

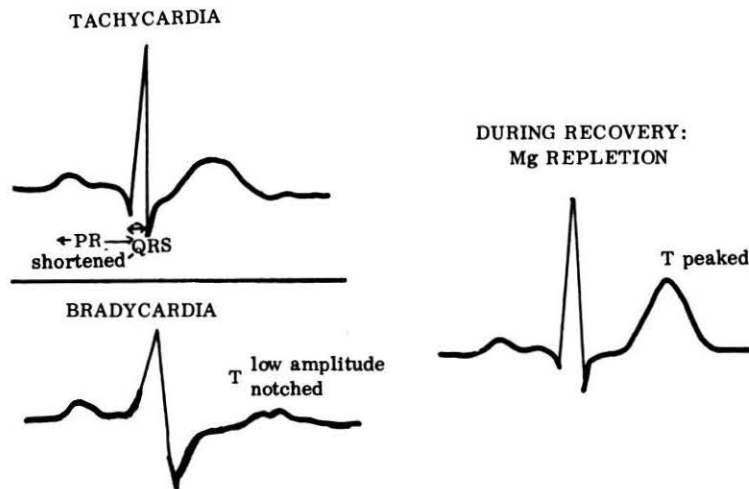


FIGURE 6. Electrocardiograms of protein-calorie malnutrition (kwashiorkor).

to the myocardial degeneration seen in kwashiorkor. Although this condition is primarily a protein-deficiency disease, Cadell<sup>80-82</sup> has shown that magnesium depletion is also present, and she has recorded electrocardiograms from her patients resembling those of experimental magnesium-deficiency (FIGURE 6). There was a high mortality rate in children with flat, or inverted T waves, such as has been seen in severely magnesium-depleted animals. During the recovery period, elevated, sharply peaked T waves were seen.<sup>80</sup> Examination of the recovery patterns of children with protein-calorie malnutrition on magnesium therapy, as well as of alcoholic heart disease patients, shows that both have peaked T waves, such as is seen with dogs that have moderately-advanced magnesium-depletion. Prior to recovery, in both instances, the patterns resemble more closely the pattern of severe magnesium depletion.

The similarity of the magnesium-depletion ECG to that of hypercalcemia calls attention to another clinical syndrome associated with myocardial damage and ECG changes—infantile hypercalcemia<sup>83-85</sup> (see FIGURE 7). The ECG changes, reported by Coleman,<sup>83,84</sup> are confined to the ST-T complex. The ST segment was found to be elevated; the T wave was unusually broad and prominent. In a few instances, the summit of the T wave was flattened and either formed a plateau or was slightly notched—in this regard resembling one of the patterns seen in alcoholic heart disease. This condition has been associated with either excessive administration of vitamin D, or with excessive reactivity to customary vitamin D supplements.<sup>83-87</sup> Since vitamin D excess has been associated with magnesium loss,<sup>47</sup> and with myocardial injury in experimental animals,<sup>84-86</sup> it is possible that the cardiovascular lesions of infantile hypercalcemia may be related to the metabolic derangements that occur with loss of tissue magnesium. Arguing in favor of this concept is the observation by Coleman,<sup>83</sup> that even when the serum levels of calcium were returned to normal, the abnormalities in the ST-T complex often persisted.

In each of the foregoing instances, the electrocardiographic abnormalities have been almost entirely in the S-T segment and in the T wave patterns. Changes in these areas are also seen in clinical myocardial disease, including ischemia,

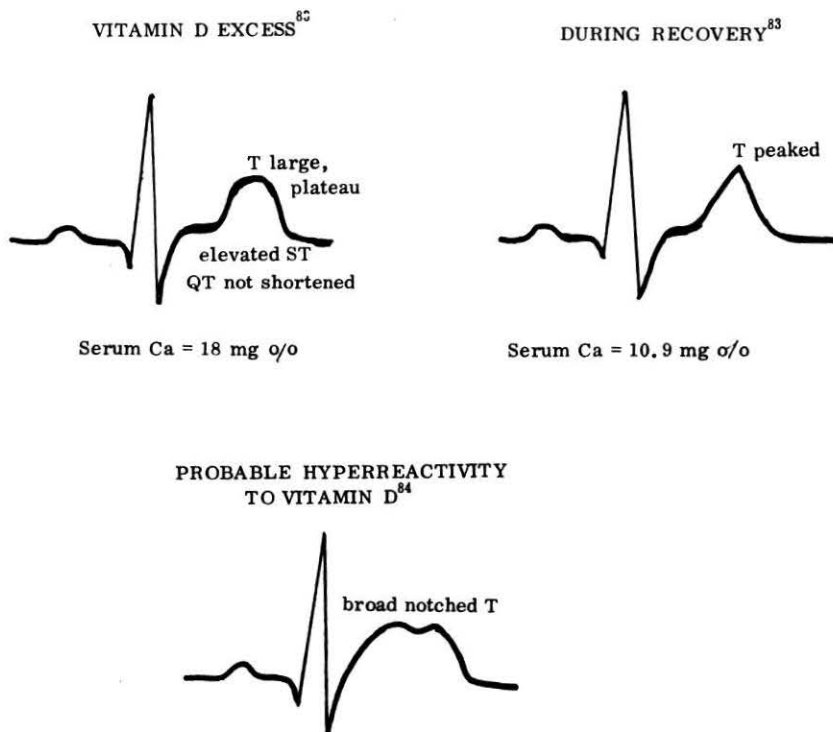


FIGURE 7. Electrocardiograms of infantile hypercalcemia.

infarction, and myocarditis caused by many disorders.<sup>88-90</sup> Samson and Scher<sup>91</sup> have analyzed the mechanism by which acute myocardial ischemic injury, caused by coronary ligation, causes alterations in the S-T segment. They found that changes in the intracellular action potential can be correlated with ECG changes. Köhler<sup>92</sup> has reviewed the evidence that the ECG alteration of ischemia are causally related to the marked decrease in intracellular potassium and magnesium with resultant disruption of metabolic processes involving high energy phosphates. Inducing myocardial necrosis by apparently unrelated experimental techniques, Selye,<sup>17,18</sup> Bajusz,<sup>19</sup> and Lehr and his coworkers<sup>23,93</sup> have shown that loss of tissue magnesium precedes the necrotic changes. Consistent and highly significant tissue depletion of magnesium and phosphate, followed by loss of tissue potassium and gain of tissue calcium was correlated with swelling and cystic degeneration and enlargement of the sarcotubular system of myocardial cells.<sup>93</sup> In all of these experimental studies,<sup>17-19,93</sup> simultaneous administration of  $MgCl_2$ , with and without KCl, prevented both the electrolyte shift and the cardiac injury. The loss of tissue magnesium in Lehr's experimental animals occurred sooner and persisted longer after removal of the challenge than the loss of tissue potassium, and was associated with electrocardiographic changes that primarily involved the T wave and the duration of the Q-T interval.<sup>93</sup>

Electron microscopic findings similar to those found by Heggveit, Herman, and Mishra<sup>15,94-96</sup> in the hearts of magnesium-depleted rats, have been reported by Alexander<sup>97</sup> and by Hibbs and coworkers<sup>98</sup> in the myocardium from



patients with alcoholic heart disease, and by Lehr and colleagues<sup>23,93</sup> in myocardial damage caused by pharmacological challenge. In all instances, myocardial fibers were destroyed or fragmented, swollen mitochondria were densely packed into areas formerly occupied by myofibers, and there was dilatation or swelling of the sarcoplasmic reticulum. The prevention by magnesium of myocardial sarcosomal swelling and dysfunction has been demonstrated by Nakamura, Vitale, and diGiorgio and their coworkers<sup>99-101</sup> in dietary studies, and by Lehr and his coworkers in pharmacological studies.<sup>23,93</sup>

The many indications of the importance of magnesium in cellular metabolism, and in maintaining myocardial integrity, indicate the need for diagnostic tools that will demonstrate the significance of magnesium loss and clinical response to repletion. Plasma levels provide an unreliable index to the status of muscle magnesium. Skeletal muscle biopsy has been used, but this technique cannot be utilized for the direct measurement of myocardial magnesium in human subjects. A disturbance of the metabolism of the myocardial cell, particularly with regard to phosphorylation and dephosphorylation, impairs the restitutive cation shifts, which in turn causes electrophysiological changes. Study of the electrocardiogram, with consideration of the patterns of magnesium deficiency may provide a means of detecting changes in the electrical events in the myocardium that result from shifts of magnesium, potassium, and phosphates out of the cell. Lehr<sup>93</sup> has suggested that the early electrolyte shifts may be subcellular, with shifts of magnesium out of the mitochondria and failure of phosphate transfer into the mitochondria. Since magnesium plays a vital role in the enzymatic processes of the cell, its loss probably contributes to the mitochondrial and then cellular disruption of the myocardium seen in conditions associated with magnesium depletion.

If the ECG changes of alcoholism are related to such ionic shifts, as well as to the consequent myocardial necrosis, magnesium repletion should be associated with alterations in the patterns. ECG improvement on magnesium therapy of acute alcoholism has already been demonstrated in a few studies.<sup>66-68</sup> What is needed is additional attention paid to the ECG of acute and chronic alcoholism, with tracings taken during the recovery and convalescent periods. It is suggested that magnesium be used, not only in the treatment of the patient with delirium tremens of acute alcoholism, but also in the chronic alcoholic with heart disease, and that the patterns of response be followed electrocardiographically. If used early enough, magnesium, added to other supportive therapy, may prevent irreversible myocardial damage.

#### References

1. FLINK, E. B. 1969. Therapy of Magnesium Deficiency. (This monograph.)
2. JONES, E., S. R. SHANE, W. H. JACOBS & E. B. FLINK. 1969. Magnesium balance studies in chronic alcoholism. (This monograph.)
3. MENDELSON, J. H. 1969. Effects of Alcohol Ingestion and Withdrawal on Magnesium States of Alcoholics: Clinical and Experimental Findings. (This monograph.)
4. SULLIVAN, J. F., P. W. WOLPERT, R. WILLIAMS & J. D. EGAN. Serum magnesium in chronic alcoholism. (This monograph.)
5. WALLACH, S. & A. DIMICH. 1969. Radiomagnesium turnover studies in hypomagnesemic states. (This monograph.)
6. WOLFE, S. M. & M. VICTOR. 1969. The relationship of hypomagnesemia and alkalosis to alcoholic withdrawal symptoms. (This monograph.)
7. MOORE, L. A., E. T. HALLMAN & L. B. SHOLL. 1938. Cardiovascular and other lesions in calves fed diets low in magnesium. *A.M.A. Arch. Path.* 1: 820-838.
8. ARNOLD, R. M. & I. H. FINCHAM. 1950. Cardiovascular and pulmonary calcification apparently associated with dietary imbalance in Jamaica. *J. Comp. Path.* 60: 51-66.

9. HELLERSTEIN, E. E., J. J. VITALE, P. L. WHITE, D. M. HEGSTED, N. ZAMCHECK & M. NAKAMURA. 1957. Influence of dietary magnesium on cardiac and renal lesions of young rats fed an atherogenic diet. *J. Exp. Med.* **106**: 767-775.
10. VITALE, J. J., E. E. HELLERSTEIN, D. M. HEGSTED, M. NAKAMURA & A. FARBMAN. 1959. Studies on the interrelationships between dietary magnesium and calcium in atherogenesis and renal lesions. *Amer. J. Clin. Nutr.* **7**: 13-22.
11. NAKAMURA, M., J. J. VITALE, D. M. HEGSTED & E. E. HELLERSTEIN. 1960. The effect of dietary magnesium and thyroxine on progression and regression of cardiovascular lipid deposition in the rat. *J. Nutrition* **71**(4): 347-355.
12. VITALE, J. J., E. E. HELLERSTEIN, M. NAKAMURA & B. LOWN. 1961. Effects of magnesium-deficient diet upon puppies. *Circ. Res.* **9**(2): 387-394.
13. VITALE, J. J., H. VELEZ, C. GUZMAN & P. CORREA. 1963. Magnesium deficiency in the cebus monkey. *Circ. Res.* **12**(6): 642-650.
14. MISHRA, R. K. 1960. Studies on experimental magnesium deficiency in the albino rat. *Rev. Canadienne de Biol.* **19**(2): 122-135.
15. HEGGTVEIT, H. A., L. HERMAN & R. K. MISHRA. 1964. Cardiac necrosis and calcification in experimental magnesium deficiency. *Am. J. Path.* **45**(5): 757-782.
16. LARVOR, P., A. GIRARD, M. BROCHART, A. PARODI & J. SEVESTRE. 1964. Etude de la carence experimentale en magnesium chez le veau. *Ann. Biol. Anim. Biochem. Biophys.* **4**(4): 345-369.
17. SELYE, H. 1958. The chemical prevention of cardiac necrosis. Ronald Press. New York, N. Y.
18. SELYE, H. 1958. Prophylactic treatment of an experimental arteriosclerosis with magnesium and potassium salts. *Amer. Heart J.* **55**(6): 805-809.
19. BAJUSZ, E. 1965. Nutritional Aspects of Cardiovascular Diseases. J. B. Lippincott Co. Philadelphia and Montreal.
20. HELLERSTEIN, E. E., M. NAKAMURA, D. M. HEGSTED & J. J. VITALE. 1960. Studies on the interrelationships between dietary magnesium, quality and quantity of fat, hypercholesterolemia and lipidosis. *J. Nutrition* **71**: 339-346.
21. BAJUSZ, E., Ed. 1965. Electrolytes and Cardiovascular Diseases. Vol. I. S. Karger, Basel, Switzerland & New York, N. Y.
22. BAJUSZ, E., Ed. 1965. Electrolytes and Cardiovascular Diseases. Vol. II. S. Karger, Basel, Switzerland & New York, N. Y.
23. LEHR, D., M. KRUKOWSKI & R. COLON. 1966. Correlation of myocardial and renal necrosis with tissue electrolyte changes. *J.A.M.A.* **197**(2): 145-152.
24. MALKIEL-SHAPIRO, B., I. BERSOHN & P. E. TERNER. 1956. Parenteral magnesium sulphate therapy in coronary heart disease. *Med. Proc.* **2**: 455-462.
25. AGRANAT, A. L. 1968. Parenteral magnesium sulphate in the treatment of angina pectoris: an evaluation. *Med. Proc.* **4**: 67-76.
26. MARAIS, A. F. 1958. Magnesium sulphate in coronary artery disease: case records. *Med. Proc.* **4**: 66-67.
27. TEEGER, A. 1958. Magnesium sulphate in coronary artery disease: case records. *Med. Proc.* **4**: 77-78.
28. PARSONS, R. S. 1958. The biochemical changes associated with coronary artery disease treated with magnesium sulphate. *Med. J. Aust.* **1**: 883-884.
29. PARSONS, R. S., T. BUTLER & E. P. SELLARS. 1959. The treatment of coronary artery disease with parenteral magnesium sulphate. *Med. Proc.* **5**: 487-498.
30. ANONYMOUS. 1960. Magnesium and coronary disease. (An editorial.) *Brit. Med. J.* (1960): 1949.
31. MALKIEL-SHAPIRO, B. & I. BERSOHN. 1960. Magnesium sulphate in coronary thrombosis. *Brit. Med. J.* **1**: 292.
32. PARSONS, R. S., T. BUTLER & E. P. SELLARS. 1960. Coronary artery disease: further investigations on its treatment with parenteral magnesium sulphate and incorporating minimal doses of heparin. *Med. Proc.* **6**: 479-486.
33. BROWNE, S. E. 1961. Magnesium sulphate in the treatment of angina. *Lancet* **2**: 1313-1314.
34. BROWNE, S. E. 1963. Magnesium and cardiovascular disease. *Brit. Med. J.* **2**: 118.
35. BROWNE, S. E. 1964. Parenteral magnesium sulphate in arterial disease. *Practitioner* **192**: 791-797.
36. DURLACH, J. 1967. Magnesium-deficiency thrombosis. *Lancet* **1**: 1382.
37. DURLACH, J. 1967. Le role antithrombotique physiologique du magnesium. *Coeur et Medecine Interne* **6**(2): 213-232.
38. DURLACH, J. 1967. Le magnesium en pathologie humaine. *Gazette Medicale de France* **74**(17): 3303-3320.

39. DURLACH, J. & M. CACHIN. 1967. Magnesium et alcoolisme chronique. *Revue de L'Alcoolisme* 13(1): 3-40.
40. LEPESCHKIN, E. 1959. The role of electrolytes in metabolic influences on the electrocardiogram. *Adv. Cardiol.* 2: 189-212.
41. WEAVER, W. F. & H. B. BURCHELL. 1960. Serum potassium and the electrocardiogram in hypokalemia. *Circulation* 21: 505-521.
42. WINSOR, T. 1968. Electrolyte abnormalities and the electrocardiogram. *J.A.M.A.* 203(5): 109.
43. SURAWICZ, B. & E. LEPESCHKIN. 1953. The electrocardiographic pattern of hypopotassemia with and without hypocalcemia. *Circulation* 8(6): 801-828.
44. COTLOVE, E., M. A. HOLLIDAY, R. SCHWARTZ & W. M. WALLACE. 1951. Effects of electrolyte depletion and acid-base disturbance on muscle cations. *Am. J. Physiol.* 167(3): 665-675.
45. MACINTYRE, I. & D. DAVIDSSON. 1958. The production of secondary potassium depletion, sodium retention, nephrocalcinosis and hypercalcemia by magnesium deficiency. *Biochem. J.* 70: 456-462.
46. WHANG, R. & L. G. WELT. 1963. Observations in experimental magnesium depletion. *J. Clin. Invest.* 42(3): 305-313.
47. WELT, L. G. 1964. Experimental magnesium depletion. *Yale J. Biol. Med.* 36: 325-349.
48. SETA, K., E. E. HELLERSTEIN & J. J. VITALE. 1965. Myocardium and plasma electrolytes in dietary magnesium and potassium deficiency in the rat. *J. Nutrition* 87(2): 179-188.
49. FITZGERALD, M. G. & P. FOURMAN. 1956. An experimental study of magnesium deficiency in man. *Clin. Sci.* 15: 635-647.
50. ANONYMOUS. 1959. Magnesium depletion. (An editorial) *Lancet*: 820-822.
51. MACINTYRE, I., S. HANNA, C. C. BOOTH & A. E. READ. 1961. Intracellular magnesium deficiency in man. *Clin. Sci.* 20: 297-305.
52. SHILS, M. E. 1964. Experimental human magnesium depletion. I. Clinical observations and blood chemistry alterations. *Amer. J. Clin. Nutr.* 15: 133-143.
53. GITELMAN, H. J., S. KUKOLJ & L. G. WELT. 1968. The influence of the parathyroid glands on the hypercalcemia of experimental magnesium depletion in the rat. *J. Clin. Invest.* 47(1): 118-126.
54. LARVOR, P., A. GIRARD & M. BROCHART. 1964. Etude de la carence experimentale en magnesium chez le veau. *Ann. Biol. Anim. Bioch., Biophys.* 4(4): 371-382.
55. MARTIN, H. E., H. EDMONDSON, R. HOMANN & C. F. BERNE. 1950. Electrolyte problems in the surgical patient, with particular reference to serum calcium, magnesium and potassium levels. *Am. J. Med.* 8: 529-530.
56. BOOTH, C. C., S. HANNA, N. BABOURIS & I. MACINTYRE. 1963. Incidence of hypomagnesaemia in intestinal malabsorption. *Brit. Med. J.* 2: 141-143.
57. GOLDMAN, A. S., D. D. VAN FOSSAN & E. E. BAIRD. 1962. Magnesium deficiency in celiac disease. *Pediatrics* 29(6): 948-952.
58. PETERSON, V. P. 1963. Metabolic studies in clinical magnesium deficiency. *Acta Med. Scandinav.* 173: 285-298.
59. SETA, K., R. KLEIGER, E. E. HELLERSTEIN, B. LOWN & J. J. VITALE. 1966. Effect of potassium and magnesium deficiency on the electrocardiogram and plasma electrolytes of pure-bred Beagles. *Amer. J. Cardiol.* 17: 516-519.
60. ONO, I. 1962. The effect of varying dietary magnesium on the electrocardiogram and blood electrolytes of dogs. *Jap. Circ. J.* 26: 677-685.
61. SYLLM-RAPOPORT, I. 1962. Electrocardiographic studies in dogs with experimental magnesium deficiency. *Journal of Pediatrics* 60(5): 801-804.
62. WENER, J., K. PINTAR, M. A. SIMON, R. MOTOLA, R. FRIEDMAN, A. MAYMAN & R. SCHUCHER. 1964. The effects of prolonged hypomagnesemia on the cardiovascular system in young dogs. *Am. Heart J.* 67(2): 221-231.
63. KRUSE, H. D., E. R. ORENT & E. V. MCCOLLUM. 1932. Studies on magnesium deficiency in animals. I. Symptomatology resulting from magnesium deprivation. *J. Biol. Chem.* 96: 519-539.
64. GREENBERG, D. M. & E. V. TUFTS. 1938. The nature of magnesium tetany. *Am. J. Physiol.* 121: 416-423.
65. MILLER, E. R., D. E. ULLREY, R. W. DANIELS, R. K. RINGER & J. A. HOEFER. 1964. Electrocardiographic changes with dietary deficiencies of magnesium, calcium or vitamin D in the baby pig. *Fed. Proc.* 23(2): 290, Part I.
66. FLINK, E. B., F. L. STUTZMAN, A. R. ANDERSON, T. KONIG & R. FRASER. 1954. Magnesium deficiency after prolonged parenteral fluid administration and after chronic alcoholism complicated by delirium tremens. *J. Lab. Clin. Med.* 43(2): 169-183.

67. FLINK, E. B., R. MCCOLLISTER, A. S. PRASAD, J. C. MELBY & R. P. DOE. 1957. Evidences for clinical magnesium deficiency. *Ann. Int. Med.* **47**: 956-968.
68. SMITH, W. O. & J. F. HAMMARSTEN. 1959. Intracellular magnesium in delirium tremens and uremia. *Amer. J. Med. Sci.* **237**: 413-417.
69. BRIGDEN, W. & J. ROBINSON. 1964. Alcoholic heart disease. *Brit. Med. J.* **2**: 1283-1289.
70. ALEXANDER, C. S. 1966. Idiopathic heart disease. I. Analysis of 100 cases, with special reference to chronic alcoholism. *Am. J. Med.* **41**: 213-228.
71. BURCH, G. E. & J. J. WALSH. 1960. Cardiac insufficiency in chronic alcoholism. *Am. J. Cardiol.* **6**(5): 864-874.
72. PRIEST, R. G., J. K. BINNS & A. H. KITCHIN. 1966. Electrocardiogram in alcoholism and accompanying physical disease. *Brit. Med. J.* **1**: 1453-1455.
73. WENDT, V. E., C. WU, R. BALCON, G. DOTY & R. J. BING. 1965. Hemodynamic and metabolic effects of chronic alcoholism in man. *Am. J. Cardiol.* **15**: 175-184.
74. SWANK, R. L., R. R. PORTER & A. YEOMANS. 1941. The production and study of cardiac failure in thiamine-deficient dogs. *Am. Heart J.* **22**: 154-168.
75. ASHBURN, L. L. & J. V. LOWRY. 1944. Development of cardiac lesions in thiamine-deficient rats. *Arch. Path.* **37**: 27-33.
76. RINEHART, J. F., L. D. GREENBERG & M. FRIEDMAN. 1947. Experimental thiamine deficiency in the rhesus monkey. *Am. J. Path.* **23**: 879-881.
77. ZIEVE, L. 1969. Influence of magnesium deficiency on the utilization of thiamine. (This monograph.)
78. AIKAWA, J. K. 1960. Effects of pyridoxine and desoxypyridoxine on magnesium metabolism in the rabbit. *Proc. Soc. Exp. Biol. Med.* **104**: 461-463.
79. SERONDE, J. 1960. Cardiac lesions and related findings in young vitamin B<sub>6</sub>-deficient rats. *J. Nutrition* **72**: 53-65.
80. CADDELL, J. L. 1965. Magnesium in the therapy of protein-calorie malnutrition of childhood. *Pediatrics* **66**: 392-413.
81. CADDELL, J. L. 1967. Studies in protein-calorie malnutrition. II. A double blind clinical trial to assess magnesium therapy. *New Eng. J. Med.* **276**(10): 535-540.
82. CADDELL, J. L. & D. R. GODDARD. 1967. Studies on protein-calorie malnutrition. I. Chemical evidence for magnesium deficiency. *New Eng. J. Med.* **276**(10): 533-535.
83. COLEMAN, E. N. 1959. Electrocardiographic changes in idiopathic hypercalcaemia of infancy. *Brit. Med. J.* **2**: 467-470.
84. COLEMAN, E. N. 1965. Infantile hypercalcaemia and cardiovascular lesions. *Arch. Dis. Childh.* **40**: 535-540.
85. SEELIG, M. S. 1969. Vitamin D and cardiovascular, renal, and brain damage in infancy and childhood. *Ann. N. Y. Acad. Sci.* **147**(15): 537ff.
86. GILLMAN, J. & C. GILBERT. 1956. Calcium phosphorus and vitamin D as factors regulating the integrity of the cardiovascular system. *Exp. Med. Surg.* **14**: 136-168.
87. LIGHTWOOD, R., W. SHELDON, C. HARRIS & T. STAPLETON. 1956. Hypercalcemia in infants and vitamin D. *Brit. Med. J.* **2**: 149.
88. ARMSTRONG, M. L. 1965. Electrocardiograms. A Systematic Method of Reading Them. John Wright & Sons, Ltd. Bristol, England.
89. IRVING, D. W. 1968. Diffuse myocardial disease. *JAMA* **203**(11): 193.
90. MARRIOTT, H. J. L. & M. M. MENENDEZ. 1967. Noncoronary disease simulating myocardial ischemia or infarction. *JAMA* **201**(1): 131.
91. SAMSON, W. E. & A. M. SCHER. 1960. Mechanism of S-T segment alteration during acute myocardial injury. *Circ. Res.* **8**: 780-787.
92. KÖHLER, J. A. 1965. The Importance of Recent Biochemical-electrophysiological Discoveries—Potassium Ion and Myocardium "Extra-situ"—for Clinical Electrocardiography in Electrolytes and Cardiovascular Diseases. E. Bajusz, Ed. **2**: 61-99. S. Karger. Basel, Switzerland & New York, N. Y.
93. LEHR, D. 1969. Tissue electrolyte alteration in disseminated myocardial necrosis. *Ann. N. Y. Acad. Sci.* **156**(1): 344-378.
94. MISHRA, R. K. 1960. Studies on experimental magnesium deficiency in the albino rat. II. The influence of Mg-deficient diet on mitochondrial population of heart, kidney and liver. *Rev. Canadienne de Biol.* **19**(2): 136-142.
95. MISHRA, R. K. & L. HERMAN. 1960. Preliminary observations on the ultrastructure of rat cardiac muscle following a Mg-deficient regime and cold stress. : 907-911. *Proc. European Reg. Conf. on Electron Microscopy*. Delft, The Netherlands.
96. HEGGTVEIT, H. A. 1965. The Cardiomyopathy of Magnesium-deficiency in Electrolytes and Cardiovascular Diseases. **1**: 204-220. E. Bajusz, Ed. S. Karger. Basel, Switzerland & New York, N. Y.

97. ALEXANDER, C. S. 1966. Idiopathic heart disease. II. Electron microscopic examination of myocardial biopsy specimens of alcoholic heart disease. *Am. J. Med.* **41**: 229-234.
98. HIBBS, R. G., V. J. FERRANS, W. C. BLACK, D. G. WEILBAEGER, J. J. WALSH & G. E. BURCH. 1965. Alcoholic cardiomyopathy. An electron microscopic study. *Am. Heart J.* **69**(6): 766-779.
99. NAKAMURA, M., M. NAKATANI, M. KOIKE, S. TORII & M. HIRAMATSU. 1961. Swelling of heart and liver mitochondria from magnesium deficient rats and its reversal. *Proc. Soc. Exper. Biol. Med.* **108**(2): 315-319.
100. VITALE, J. J., M. NAKAMURA & D. M. HEGSTED. 1957. The effect of magnesium deficiency on oxidative phosphorylation. *J. Biol. Chem.* **228**: 573-576.
101. DI GIORGIO, J., J. J. VITALE & E. E. HELLERSTEIN. 1962. Sarcosomes and magnesium deficiency in ducks. *Biochem. J.* **82**: 184-187.