

VITAMIN D AND CARDIOVASCULAR, RENAL, AND BRAIN DAMAGE IN INFANCY AND CHILDHOOD

MILDRED S. SEELIG*

*Adjunct Assistant Professor, Pharmacology
New York Medical College,
Flower and Fifth Avenue Hospitals
and
Research Associate, Pediatrics
Maimonides Medical Center,
Brooklyn, N.Y.*

INTRODUCTION

There has been increasing notice taken in the literature of recent years of a presumed congenital abnormality characterized by supra-auricular aortic stenosis, a peculiar facies and severe mental retardation. That an hereditary genetic defect may play a part in this syndrome has been suggested. The possibility that this syndrome may be induced by excess vitamin D during gestation has also been considered. This paper presents the possibility that this syndrome is an expression of hyper-reactivity to vitamin D that can be especially severe during early infancy. There is evidence that it may be the anatomic consequence of the disease known as hypercalcemia of infancy, which many investigators have found to develop in infants receiving doses of vitamin D that are only slightly to moderately above those considered prophylactic. This paper presents evidence that generalized arteriosclerosis of infancy may be the most severe manifestation of vitamin D toxicity in infants with marked susceptibility to vitamin D, and that renal acidosis may be a less severe expression of this sensitivity. There is evidence that recommended daily dosages of vitamin D may be toxic for some susceptible people, and that the potency of vitamin D is significantly greater in milk than in oil. As Taussig¹ has recently observed, the inborn "variant" in the metabolism of vitamin D that made some children less prone to rickets in the days before unlimited vitamin D supplementation of our foods is now the so-called "inborn error of metabolism" that may be responsible for vitamin D-induced injury to the cardiovascular, renal, and central nervous systems.

*Present Address: Schering Corporation
Bloomfield, N.J.

THE SUPRAVALVULAR AORTIC STENOSIS SYNDROME

Williams *et al.*² first called attention (in New Zealand in 1961) to the association of severe mental retardation and a peculiar facies with supra-valvular aortic stenosis in young patients with retarded growth (see FIGURE 1). Upon reviewing the literature on similar cases, they discovered that in two of the studies, the patients were found at autopsy to have had fibrous myocarditis and myocardial atrophy.^{3,4} Since they suspected a myocardial abnormality in one of their four patients, they suggested the possibility that myocardial degeneration might be another facet of this new syndrome. It is of interest that the patient reported by Burry⁴ had also been described as being congenitally mentally defective. The same year (1961), Perou⁵ reported detailed histological studies of the supra-valvular stenotic areas of the aortas of a 13-year-old boy and of a 24-year-old man who had been in a State Hospital for mental retardation. In the first case, the child's records indicated a history of malnutrition and congenital heart disease at one year of age; the facies of the second case seems to bear some relationship to that described by Williams *et al.*² The patient was described as having large ears, high and narrow palate, and irregular carious teeth, an appearance quite similar to that reported recently by Rosenthal and Doyle⁶ in a child with supra-valvular aortic stenosis. These characteristics are selected here for note because of their resemblance to those seen in survivors of infantile hypercalcemia⁷ (see FIGURE 2). Friedman⁸ has suggested that excess vitamin D during gestation may be responsible for the abnormalities of the craniofacial complex, characteristic of both the supra-valvular aortic syndrome and infantile hypercalcemia.⁸

The histological characteristics of the circular ridge and constriction at the upper margin of the sinuses of Valsalva, seen in the two cases reported by Perou, included slight intimal thickening, hyalinized fibrous tissue, fragmentation and disorientation of the elastica, and foci of necrosis and calcification. The myocardium of Perou's second patient showed patchy areas of fibrosis, and the kidneys were contracted and granular. Histological changes of the aorta had also been reported earlier by other pathologists who sectioned the stenotic portion of the aorta.^{3,4,9,10} It was Perou's conclusion that this type of supra-valvular aortic stenosis is unquestionably congenital.

Since then, additional investigators have reported similar patients with the aortic lesions, mental retardation and peculiar facies, the entire complex often described as a congenital anomaly.^{6,11-18} However, Eberle and Beuren,¹⁹ who had reported three patients with characteristics similar to those described by Williams a year later, attempted to detect chromosomal abnormalities in their patients, without success. Merritt *et al.*,²⁰ however, did find a chromosomal abnormality in one patient with the full-blown syndrome, among eight supra-valvular aortic stenotic patients studied. In four of the eight families, only the proband was affected. The remaining four families, with only the supra-valvular stenosis, had 25 probably affected individuals. In a more recent study by Kurlander *et al.*²¹ of 27 cases of supra-valvular aortic stenosis, nine also had mental retardation and peculiar facies. Chromosomal studies, performed in five of these cases, were normal.

In 1963, Black and Bonham-Carter,⁷ one of whom was a co-worker in the early study by Schlesinger *et al.*²² of an infant with hypercalcemia, noted the similarity of the appearance at the age of 11 of a survivor of that syndrome²³ to that of the children with the Williams' triad (see FIGURES 2 & 3). They

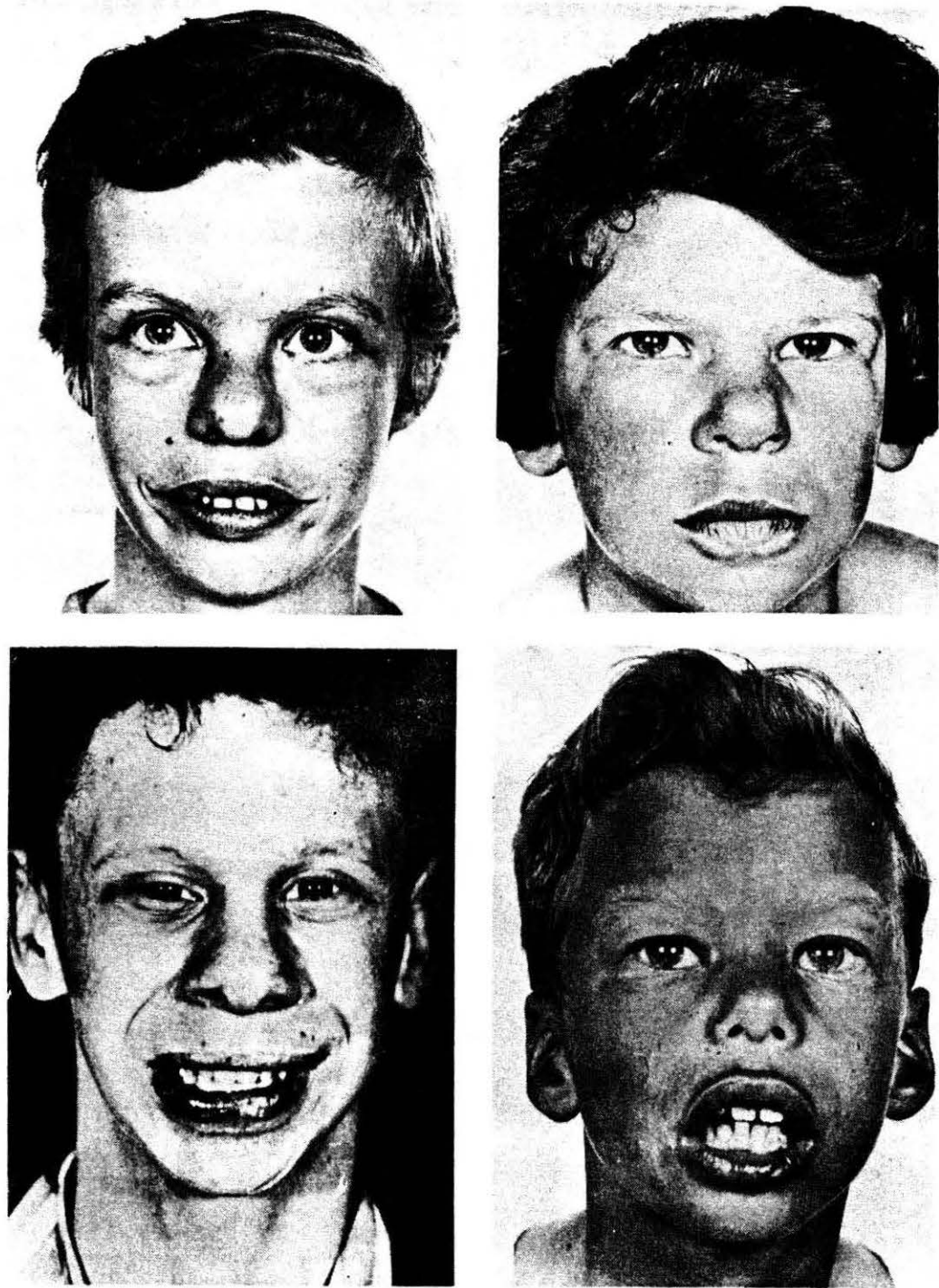

FIGURE 2. Survivors of infantile hypercalcemia. (Reproduced by permission of Black, J.A. and R.E.B. Bonham-Carter and Lancet.

presented five additional cases, all with clear histories of feeding difficulties and developmental abnormalities very similar to those seen in infants diagnosed definitively as having infantile hypercalcemia. They recently reported confirmation²⁴ at autopsy of supra-valvular aortic stenosis in the child reported earlier as hypercalcemic^{2,3} and noticed as resembling Williams' triad at the age of ten.⁷ The child died at 16 years of age with renal failure, hypertension, and left

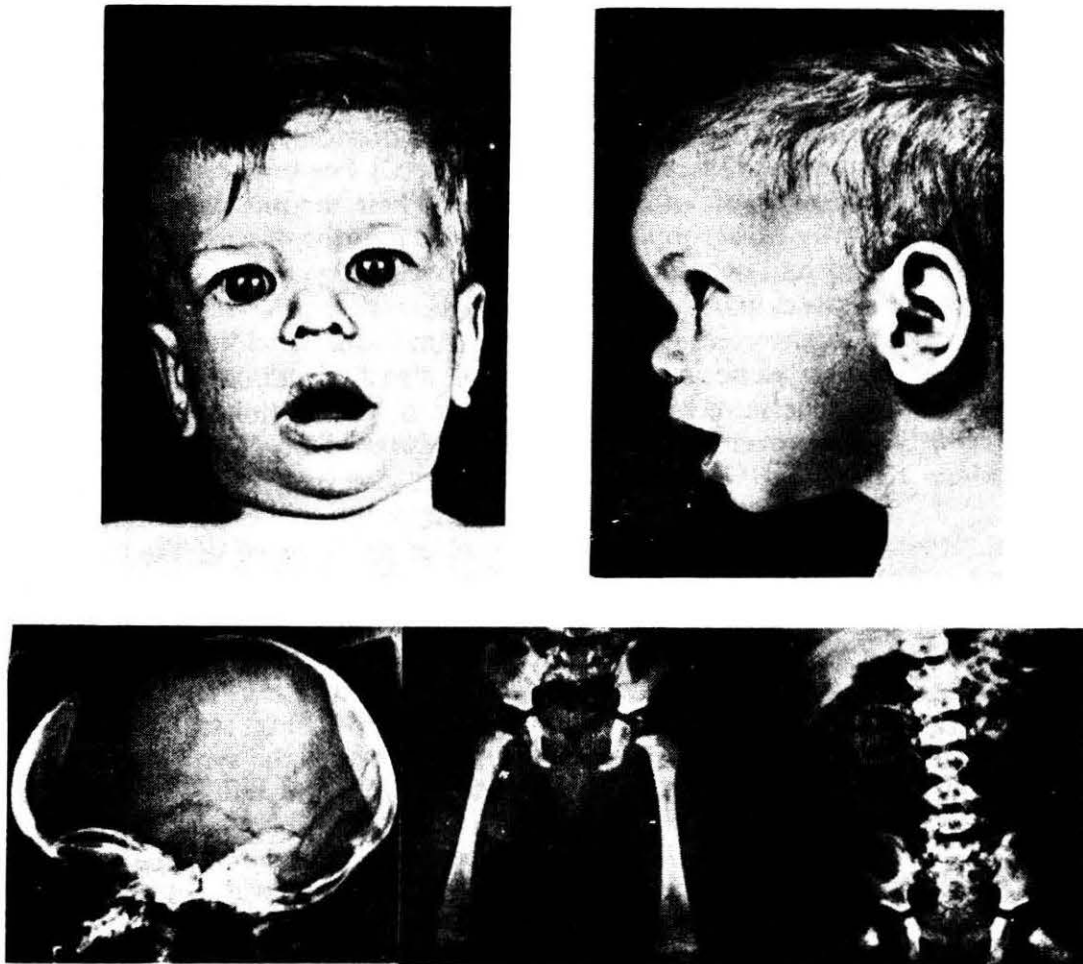


FIGURE 4. Hypercalcemic infant with supravalvular aortic stenosis. (top) Note elfin faces, high prominent forehead, epicanthal folds, underdeveloped bridge of nose and mandible, and overhanging upper lip. (bottom) Roentgenogram of skull, pelvis and long bones and spine showing diffuse osteosclerosis and bands of increased density at metaphyses and at epiphyseal margins of vertebrae. (Reproduced by permission of Garcia, R.E. *et al.* and New Eng. J. Med.)

nine-month-old infant, who had a history of a normal neonatal course. At five months, cardiomegaly and murmur had been detected; subsequent to a herniorrhaphy at six months, retarded development was noticed. The child exhibited an elfin facies, (see FIGURE 4) and on roentgenographic examination, showed considerable sclerosis of the calvaria and base of the skull, with diffuse osteosclerosis of the long bones and vertebrae. Cardiac catheterization and cineangiocardiology revealed supravalvular aortic stenosis and mild stenosis at the origin of the left pulmonary artery. This case is of particular interest in that the classic Williams' syndrome was detected early, and was correlated with both hypercalcemia and a markedly elevated vitamin D blood level (1,540 units/100 ml, as compared with the usual value range of 60-400 units). In a recent review of idiopathic hypercalcemia, Fraser *et al.*²⁶ supported the concept that supravalvular aortic stenosis, mental retardation, and peculiar facies is the late normocalcemic stage of infantile hypercalcemia.

Bauman and Bauman²⁷ reported two children with hypercalcemia and

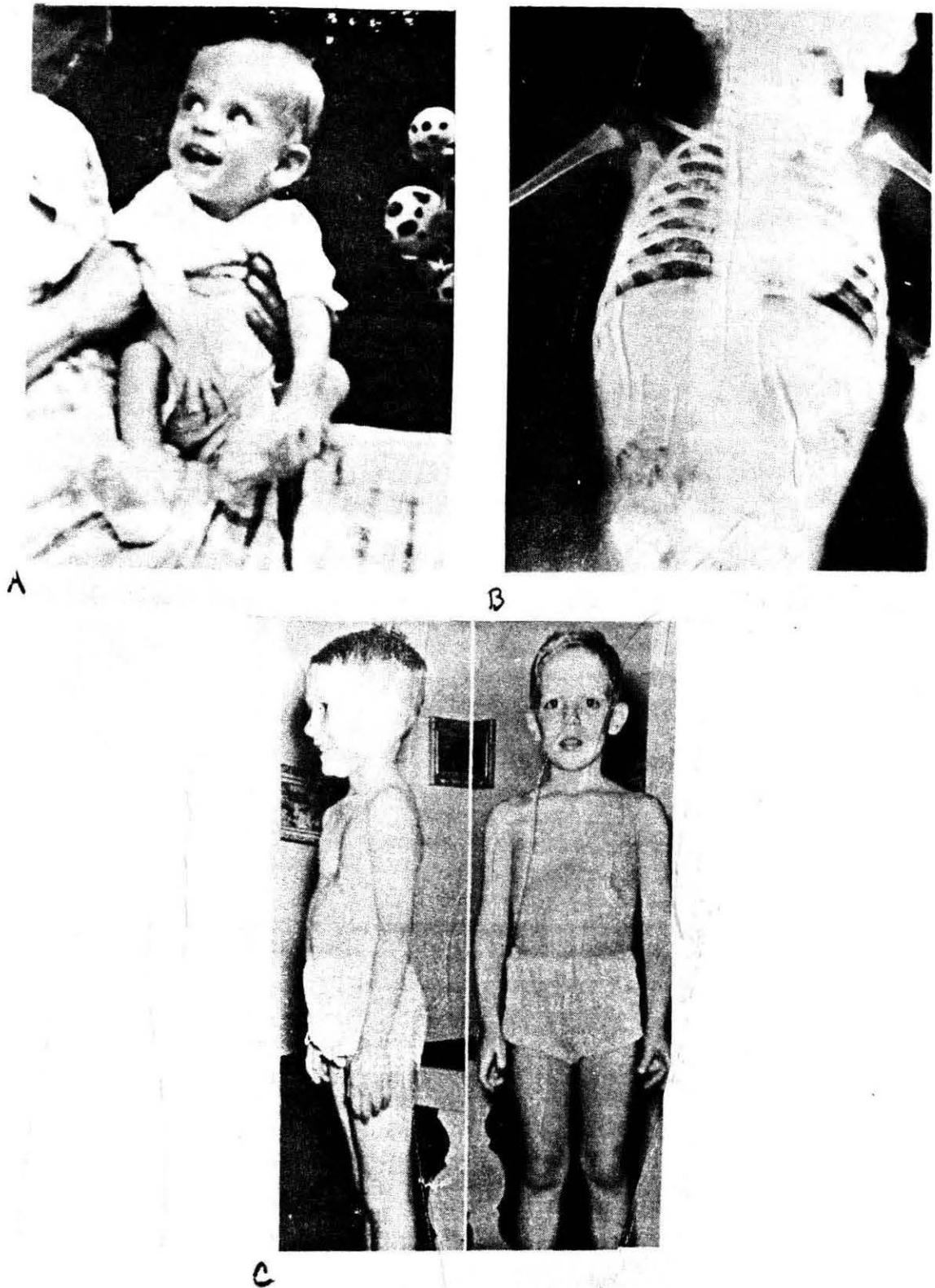


FIGURE 5. Hypercalcemic patient, who recovered on curtailment of intake of vitamin D.

A. Hypercalcemic infant: note malnutrition, poor development; low position of pinnae.
B. Roentgenogram, showing cardiac enlargement; "coar en sabot" configuration.
C. Patient, five years later, demonstrating alert appearance, good muscular development.
 (Reproduced by permission of Bauman, A. & C.G. Puman and N.Y. State J. Med.)

but also the epidemiological background and the personal histories of the patients reported, to the extent that retrospective evaluation of the published data is possible. Reference should be made to Black's review³⁸ of the relationship of vitamin D to idiopathic hypercalcemia, and to the similarities of the clinical pathology caused by overdosage with vitamin D to that of the hypercalcemia syndrome.

The full complex of chronic hypercalcemia was first described in 1952 by Schlesinger and colleagues²² and reported briefly by Lightwood³⁹ in England, and in detail by Fanconi and Girardet⁴⁰ in Switzerland. Each report dealt with a patient whose history indicated an intake of vitamin D that was not considered excessive (approximately 1,400 and 2,000 units after the first month of life.) Feeding difficulties, persistent vomiting, constipation, and failure to thrive or gain in weight characterized the early signs, with hypotonia and renal impairment seen in all three infants, Schlesinger's and Fanconi's patients also exhibited early electrocardiographic changes, and Schlesinger's patient had a harsh systolic murmur at six weeks. The patient reported by Lightwood had been referred to him because the symptoms suggested renal acidosis, a diagnosis that he excluded because of the normal plasma chloride, bicarbonate and inorganic phosphorus and because of the acidity of the urine. Each child had hypercalcemia and urea retention. Schlesinger's report included a follow-up to the age of three. The child's failure to develop normally was manifested by the age of five months. The retardation, associated with hypercholesterolemia, at first suggested the possibility of hypothyroidism, and treatment with thyroid extract was attempted, without success. By two years of age, there was definite renal impairment, hypertension, and sclerosis of bone. There appeared to be no further progression of the disease from the age of two, but at three the picture was of a mentally retarded dwarf, with defective renal function, hypertension, and a systolic murmur. The similarity of the clinical picture, at the age of two, to hypervitaminosis D led the investigators to omit vitamin D from the diet from that time on. The failure of this deletion to change the biochemical picture or to alter the clinical status led the investigators to question their original impression that the condition may have been due to hypersensitivity to vitamin D.

Analysis of the many case reports on hypercalcemia of infancy reveals that the characteristics can be divided into early, or mild and apparently reversible signs, and the later irreversible changes of the severe form of the disease. Both the mild and irreversible forms start in the early weeks or months of life with symptoms of fretfulness, anorexia, vomiting, constipation, polydipsia, polyuria, hypotonia, and cessation or marked slowing of growth and of weight gain. At this stage, blood chemistry changes include hypercalcemia (usually over 12 mg/100 ml), azotemia, and often elevated blood cholesterol (primarily the free form). Blood inorganic phosphorus may be normal or slightly elevated, and alkaline phosphatase readings are generally low. Hypercalciuria and white cells in the urine are often detected. Recurrent infection is common, the disease often becoming overt after an acute severe infection.

Several infants, detected by blood chemical studies at that stage, have been put on a low calcium diet, delivering no vitamin D.^{25-27,41-50} They exhibited fairly prompt relief of vomiting and anorexia, relief of constipation somewhat later, but persistence of elevated calcium and NPN levels for several months. Weight gain, and improvement in disposition and in muscle tone, have also been seen on such corrective diets. Corticosteroids have proven useful in inducing clinical improvement in infants with more severe manifestations.^{26,42,50-58} Hypercalcemia and decreased renal function improved,^{41,43,44,48,50,}

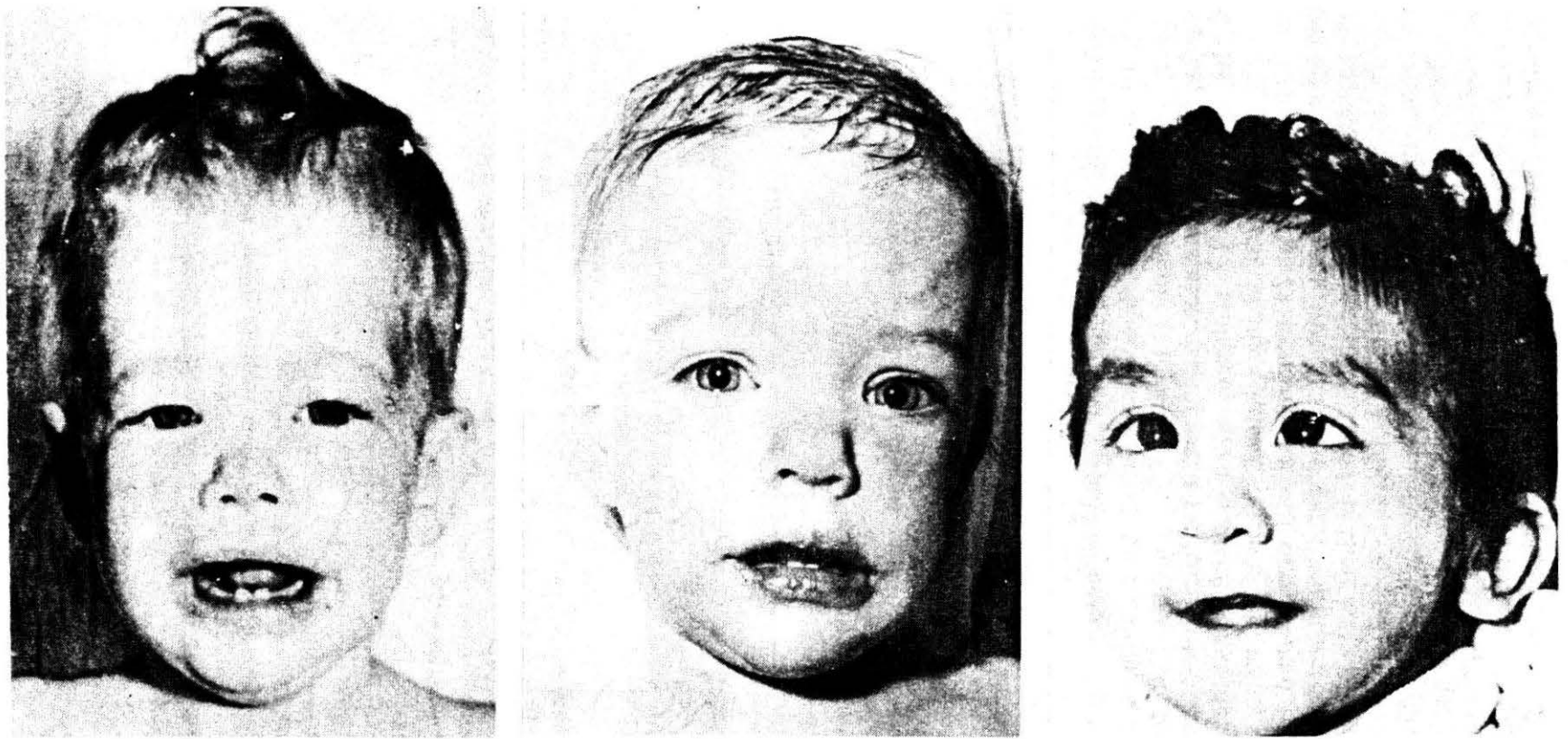

FIGURE 8. Typical facies of infantile hypercalcemia. (Reproduced by permission of O'Brien, *et al.* and J. Am. Med. Assoc.)

admitted to a medical unit in Glasgow,⁶⁵ are characterized by an abnormal shape of the ST-T complex. These changes outlasted the hypercalcemic phase of the disease and suggested to this investigator that they may reflect left ventricular myocardial lesions.

Correlation of the extremely high incidence of "idiopathic" hypercalcemia of infancy in England in the years 1953-1957 with the excessive fortification with vitamin D of National Dried Milk and other Welfare and proprietary foods suggests that Schlesinger and colleagues'²² original impression that hypersensitivity to vitamin D may have been an etiological factor may have been correct. Search of the literature has elicited over 25 articles dealing with case reports on over 80 infants who developed the syndrome during that period of time.^{7,23,24,38,39,41,43,46,49,52,56,57,60,63-78} That probably few infants so affected have been reported in print was clearly indicated by the 1956 report of the British Pediatric Association that 204 cases of hypercalcemia were reported by June, 1955 to 196 consultant pediatricians in the United Kingdom.⁷³ When the feeding difficulties, failure to thrive, the hypotonia, and susceptibility to infection characteristic of the early stage of this syndrome are taken into account, one wonders what the true incidence of this condition might have been. How many biochemical diagnoses are made among infants not brought to the attention of consultant pediatricians? How many such infants fail to survive the early months of life? How many may survive a difficult infancy, without having had biochemical tests performed, and appear later with the triad of supra-aortic stenosis, mental retardation, and facies — with renal impairment often also present? (see also, discussion of generalized arterial sclerosis of infancy, as resembling the acute hypervitaminosis D syndrome elicited in the laboratory, *vide infra*).

Despite the high frequency of infantile hypercalcemia seen in Great Britain at a time when the vitamin D intake was very high, this was not, even then, a common disease. Although it was estimated in 1955, that at least 55% of British infants were consuming excessive quantities of vitamin D⁷⁹ (FIGURE 10) only 5% of admissions of infants six to 12 months of age to the Dundee Royal Infirmary the following year were due to hypercalcemia of infancy.⁴⁹ The attention of British physicians was called to the correlation of this syndrome with excessive vitamin D in milk and cereal, as well as in cod liver oil, as early as 1954,⁸⁰⁻⁸³ the year after manufacturers were instructed to increase the fortification of National Dried Milk from 280 I.U. to 500 I.U. of vitamin D to assure delivery when marketed of the full recommended minimum of 280 I.U./dry ounce (allowing for a maximum deterioration of 44%).⁸³ One physician (Ball)⁸² wrote a letter to the editor of *Lancet* cautioning that as little as 1,000 units per day might give rise to subjective symptoms of hypervitaminosis D, and a physician (Woodcock)⁸¹ on the staff of one of the milk companies, in another letter to the editor, protested the amount of vitamin D that had to be added to milk. He referred to the early work by Jeans,⁸⁴ that demonstrated that at a daily intake of 1,800-2,000 units, growth of infants was retarded as compared with that of infants on 340-500 units in cod liver oil or even 135 units of vitamin D in milk. Creery and Neill⁸⁰ of Belfast concurred, the same year, that providing optimum or higher vitamin D intakes from both milk and cod liver oil might be related to the syndrome of hypercalcemia in infants with hypersusceptibility to the vitamin. The British Pediatric Association issued a report dated July 1955,^{73, 83} in which they referred to their 1943 recommendation of daily intake (in cod liver oil) of 500-700 I.U. of vitamin D.⁸⁵ In view of the high incidence of hypercalcemia and the high vitamin D

content of Welfare and proprietary infant foods (see TABLES 1A and 1B), they recommended that infant requirements of vitamin D be reconsidered, and that the amount added to food be lowered. An editorial, in 1956, speculated whether a hypercalcemic infant who was hypersensitive to calciferol (added to dried milk, cereals, and many concentrates) would be similarly affected by the natural vitamin D found in fish-liver oils.⁸⁶ Hubble,⁸⁷ in 1956, raised the question whether addition of vitamin D to milk and cereals might cause maximal absorption of calcium and phosphorus (a point which is discussed later in this paper). In 1957, the Ministry of Health published a report⁸⁸ on Welfare food supplementation, in which they recommended reducing (1) the vitamin D content of National Dried Milk to a minimum of 90-100 I.U./dry ounce from the minimum of 280 I.U./dry ounce; (2) the vitamin D content of infant cereals from 1,000 I.U. to 300 I.U./dry ounce; and (3) the vitamin D content of cod liver oil from 800 to 400 I.U./teaspoonful. The solution, thus, was to reduce the content of vitamin D in each of the foods to a level that would protect against rickets, should only one source be consumed. Of necessity, this means that an infant taking all three will be consuming at least three times the anti-rachitic dose. In view of the individual variation in sensitivity to vitamin D, and the demonstrated increase in potency of vitamin D when it is given in milk, (*vide infra*) it is dubious whether this provides a sufficient safety factor against causing infantile hypercalcemia in susceptible children.

In North America, for example, where the Council on Foods and Nutrition of the American Medical Association, since 1941,⁸⁹ has considered only milk containing 400 U.S.P. units of vitamin D acceptable, there have been many published reports on infants with hypercalcemia.^{2,5-27,42,44,45,47,51,54,55,61,62,90-103} It must be noted, however, that despite the official recommendation that 400 units of vitamin D from all sources meet the full daily requirement, the common fortification of foods (in addition to vitamin supplements) may lead to daily intakes that may reach as much as 2,000 units/day, or more.¹⁰⁴ Whether the occurrence of hypercalcemia of infancy in Continental Europe and Israel^{28-30,48,50,53,59,105-112,121} may also be

TABLE 1A
FORTIFICATION OF NATIONAL DRIED MILK

Date	I.U. Vitamin D per Dry Ounce	Recommendation by
1945	280	Ministry of Health ⁸⁸
1953	500	Ministry of Food ⁸³
1957	90-100	Ministry of Health ⁸⁸

TABLE 1B
CALCULATED DAILY INTAKE OF VITAMIN D (1956)⁸³

1½ pints dried milk (460 U/dry oz.):	1,725 I.U.
1 ounce cereal (1,000-1,500/dry oz.):	1,000 - 1,500 I.U.
1 tsp. cod liver oil	700-800 I.U.
Total:	3,525 - 4,025 I.U.

between the two conditions suggests that those infants who developed the full-blown syndrome of hypercalcemia of infancy, which includes renal impairment and renal calcinosis, may well have developed renal tubular acidosis on half the amount of vitamin D. The symptoms common to infantile renal acidosis include failure to thrive, vomiting, and growth retardation, symptoms that are characteristic also of hypercalcemia of infancy.^{38,67,114,115}

The association of renal acidosis with infantile hypercalcemia has been pointed out by Graham,⁴⁹ who published a summary report on 38 infants with hypercalcemia, seen at the hospital of the University of Glasgow, and on nine additional cases of hypercalcemia complicating renal acidosis during the same period. Except for the low carbon dioxide content of the plasma, the findings of all 47 infants were essentially the same. Renal calcinosis is common to both diseases. The author commented that in this hospital, renal acidosis uncomplicated by hypercalcemia was rarely seen. In a study of 60 cases of nephrocalcinosis infantum, detected at autopsy, Shanks and MacDonald¹¹⁶ observed that only 12 had belonged to the "renal acidosis" group: four were diagnosed as hyperchloremic renal acidosis, seven as idiopathic hypercalcemia, and one child had both. It was apparent that only a few of the children were recognized in life to have been suffering from one of the known causes of nephrocalcinosis. On going back over the records, vomiting was found to have been reported in 40, and constipation in 21. Prolonged administration of fortified milk and/or vitamin supplements were reported in the histories of 52. The authors presented the theory that symptomless hypercalcemia is a more wide-spread condition than has been appreciated, and that the resultant renal lesions may be detected only when the child happens to die of some other condition. It is noteworthy that in the Table giving the ante-mortem diagnoses of these patients (see TABLE 2), congenital cardiovascular abnormalities were listed in six instances, congenital central nervous system abnormalities in ten, and other renal abnormalities in three.

TABLE 2

DIAGNOSES OF 60 CASES OF NEPHROCALCINOSIS SEEN DURING 1948-57

	Congenital Abnormality	Infection	Miscellaneous	Total	Percentage Total Cases
System:					
Alimentary	5	14	8	27	45
Respiratory	—	16	—	16	26
Cardiovascular	6	—	—	6	10
Central nervous....	10	4	4	18	30
Genito-urinary (excl. nephro- calcinosis)	1	1	1	3	5
Miscellaneous Conditions:					
Renal acidosis			5		
Hypercalcemia			8		
Hypophosphatasia..			1		
Others			6		

on, the total daily intake of vitamin D from the milk formula was about 600 units. Once hypercalcemia was detected at four months, he was put on a low-calcium formula that also lacked vitamin D. The systolic murmur disappeared in one month; at 11 months he seemed normal. It was noted that the mother of this infant had received no pre-natal vitamin supplementation. The three infants reported by Michael *et al*⁹⁷ similarly recovered on discontinuing vitamin D and being put on a low calcium diet. In one instance, the infant had received only 130 units daily for the first month, and 640 units of vitamin D daily for ten days until the diagnosis was made at six weeks. Another infant received a total of 375 units daily for the first month, and 1,000 units a day for the next three months, and then 2,000 units a day for one week until the diagnosis was made. The third infant in this series received a total daily dosage of 650 units for two months before diagnosis. The infant reported by Wilkerson,⁹⁸ who died at 15 weeks of age, had never received more than 500 units daily. The condition of this infant, who had marked arterio-venous, renal, and soft tissue calcinosis, as well as hypercalcemia, may well be classified as generalized arteriosclerosis of infancy, which is compared later in this paper to the acute form of experimental hypervitaminosis D.

Among the infants diagnosed as hypercalcemic at six to 20 months of age, the early vitamin D intakes were estimated at having been probably not over 2,000 units daily in over 50 cases. One of the patients reported early by Lowe *et al*,⁶⁶ who was diagnosed at eleven months, but whose onset of clinically manifest disease was estimated from the history to have been at five months, had been breast-fed to three weeks of age, and had then been on cow's milk (probably not fortified). The intake of vitamin D from other supplemented foods was not taken into consideration. Another infant in this series had been breast-fed for four months, and was then given National Dried Milk formula until seven months, at which time clinical signs developed that led to the diagnosis of hypercalcemia at ten months of age. The third infant, who had been breast-fed for 11 weeks before being put on National Dried Milk formula, showed the first signs of the hypercalcemic syndrome at four and a half months, and was diagnosed at seven months. The remaining three infants in this series of cases had been on the fortified milk from birth. Only one of these six infants was also given cod liver oil supplements. Five survived and showed some clinical improvement on hospital diets lacking vitamin D. In this group, it is probable that after three to four months of age, all but one had received somewhat over 1,400 units of vitamin D, when all sources are considered. Total daily vitamin D intakes ranging from 500–1,400 units were reported for five infants by Forfar *et al*,⁶⁷ who three years later reported⁷⁷ that among 20 hypercalcemic infants (possibly including the five children reported previously), only rarely had any received more vitamin D than that considered optimal. Schlesinger *et al*.²³ reported that among the ten hypercalcemic infants seen by them, they were unable to find any evidence of abnormally high intakes of vitamin D by the infants, or by their mothers, prenatally, in the four cases they were able to investigate fully. However, four of the infants had received National Dried Milk formula and vitamin supplements, and thus may have received as much as 2,000 units daily, from all sources. One, who had had a history of milk intolerance, was described as having received only 750 units in cod liver oil. In this instance, it is possible that the "milk intolerance" may have been an early manifestation of vitamin D toxicity from the National Dried Milk formula. One of the infants had been breast-fed and received "vitamin supplements" until six months of age. In this instance, the diagnosis was made at 14 months. Among the 38 infants

subsequent improvement. Hubble,⁸⁷ however, gave large doses of vitamin D to two children with the mild form of the syndrome, without producing recurrence of untoward symptoms. Forfar¹²⁰ has administered large doses of calciferol (50,000–100,000 units) for about a week to three infants with hypercalcemia. In two instances, after a few days, the serum calcium rose significantly. It took about three weeks for the serum calcium to fall to pre-calciferol levels. In one case the serum calcium level fell, following the administration of calciferol, and rose again to the pre-calciferol level within a day of stopping treatment. Although hypercalcemia is an essential feature of the syndrome under discussion, the response to vitamin D loads and the degree of elevation of serum calcium apparently differ from case to case. Fraser *et al.*²⁶ have recently commented on the wide fluctuations in serum calcium which they have observed to occur spontaneously during the acute phase of the disease. Using reproducible methods for measuring serum calcium, they have seen variations of 2 to 3 mg per 100 ml within a few days in a single hypercalcemic patient. Girardet¹¹² has suggested that in certain individuals, even large doses of vitamin D may produce toxic effects without causing a substantial or sustained rise in serum calcium. His impression was based on the development of transitory albuminuria and cylindruria, with elevated NPN, after administration of single doses of vitamin D as large as 600,000 units, despite rapid return to normal of blood calcium levels that did not exceed 11 mg%.

Metabolic balance studies, showing the high percentage of dietary calcium that is absorbed (60%), has suggested to investigators that either an overaction of vitamin D,^{43,52} or defective inactivation of vitamin D⁴⁷ might cause the syndrome. Assays of vitamin D in the plasma of hypercalcemic infants have led to determination of insignificant differences from normal values in two reports,^{119,121} and to clear demonstration of markedly higher than normal values in others.^{25,58,90,91} Black³⁸ has tabulated the serum levels of vitamin D in published reports of different degrees of infantile hypercalcemia and has commented on the conflicting results. He called attention to the failure of the currently used rat line test to demonstrate the vitamin D equivalence (in man) of dihydrotachysterol (Thomas *et al.*¹⁰⁰). He has cautioned that it should not be assumed that the rat test for vitamin D activity necessarily will detect every agent in the serum which is capable of raising the serum calcium level in the human infant.

Garcia *et al.*²⁵ reported a serum value of 1,540 units in a child whose supravalvular aortic stenosis was correlated with hypercalcemia, and whose daily vitamin D intake was 400 units from milk and 1,000 units from a supplement. (The normal range of serum vitamin D in this institution was 60–400 units.) Fellers and Schwartz,^{90,91} reported serum vitamin D activity of three patients with hypercalcemia to be 20 to 30 times that seen in normal infants, even in the absence of exogenous vitamin D. Two of a set of triplets, whose vitamin D intake during their first half year of life far exceeded the amounts now considered advisable, were diagnosed by Manios *et al.*¹²² as hypercalcemic by their 23rd month, at which time all vitamin D was removed from their diets. Manios and Antener¹⁰⁵ then, three months later, demonstrated that serum vitamin D levels rose twofold from pretreatment values of 520 and 580 (as compared with the normal mean of 133 units, and the average range of 50 to 200 units), following administration of 700 I.U./d vitamin D in oil for four days.

These observations suggest that a defect in the metabolism of this vitamin plays a role in this condition. Forfar and his co-workers^{67,77,120} observed a marked increase in the free cholesterol, as well as in the calcium levels in

by Glaser *et al.*¹²⁷ presented evidence that all preparations of vitamin D in an oily vehicle, given as vitamin D₂ (prepared by electron activation of ergosterol), viosterol (ultraviolet-irradiated ergosterol), crystalline D₂, or vitamin D₃ (ultraviolet-irradiated 7-dehydrotachysterol), were effective in daily doses of 100 units in preventing clinical rickets even in premature and in Negro infants. However, because nine infants developed roentgenographic evidence, or suspicion of rickets, among the 166 who were followed for the full observation period of eight months, the authors recommended the use of 400–800 units (in oil) as a prophylactic dose.

Some insight into the difference in vitamin D requirements by racial groups may be gained by examining the findings of Warkany and Mabon.¹²⁸ They tested blood samples from 34 white children and 26 Negro children (see TABLE 3) and found that the average value of 122.6 units for the white children was about 15% higher than that for the Negro children (106.5 units). Perhaps more significant in considering factors that may play a role in diseases that may be caused by either a hypersusceptibility or a hyposusceptibility to vitamin D is the distribution of values. Six of the white children had levels twice as high as those of nine of the black children (165 and 83 units, respectively). The possibility that the generally higher anti-rachitic blood levels and greater response to vitamin D in white than in Negro children may be a consequence of the screening of ultra-violet rays by the skin pigment must be considered.

TABLE 3
FREQUENCY DISTRIBUTION OF PERSONS ACCORDING TO LEVELS OF
VITAMIN D IN BLOOD SERUM

U.S.P. Units per 100 cc. of Blood Serum	Total No. Tested	White Adults	White Children	Negro Children
165	9	2	6	1
132	27	10	11	6
110	31	14	10	7
94	8	2	4	2
83	13	1	3	9
66	1	1	0	0
Total	89	30	34	25
Average vitamin D level, units per 100 cc	116.4	117.6	122.6	106.5

From J. Warkany & H.E. Mabon. 1940. American J. Dis. Children.

The work demonstrating the ability of melanin or keratin in the skin to screen out ultra-violet light, thereby allowing for much greater exposure to sun without formation of excessive vitamin D, has recently been summarized by Loomis.¹²⁹ On the basis of the observation by Bekemeier¹³⁰ that 1 sq cm of white human skin synthesizes up to 18 units of vitamin D in three hours, Loomis¹²⁹ calculated that exposure to the skin of the cheeks of fair, thin-skinned children provides about 400 units daily. He postulated that as man moved north, and as he was exposed less and less to the rays of the sun, the fairer-skinned individuals had a survival advantage over those with darker skins,

TABLE 4

COMPARISON OF HEALING, AMONG 36 RACHITIC INFANTS, BROUGHT ABOUT BY CRYSTALLINE VITAMIN D INCORPORATED IN MILK OR IN CORN OIL

Case	Age (Mo.)	Date Begun	Menstruum in which Crystalline Vitamin D was Incorporated	No. of Rat Units (Steenbock) Given	Roentgenologic Rickets					Comment	
					At Onset	Healing after 4 Wk.	Healing after 6 Wk.	Healing after 8 Wk.	Healing after 10 Wk.		
C.M.	8	1/23	Milk†	45	Moderate	+	++	+++	++++	Porto Rican	
B.G.	6	1/25			Moderate	+	+±	++	++±	Porto Rican	
F.S.	13	1/26			Moderate	0	0			Negro	
E.D.	6	2/7			Slight	+	++	+++±		Italian	
G.N.	8	2/18			Moderate	+	+±	++	+++	Porto Rican	
C.W.	22	2/17			Marked	+±	++	++±		Negro	
G.B.	8	2/21			Moderate	+±	+++±	+++±		Negro	
J.N.	6	2/24			Mild	0	0	0 (worse)		Negro	
V.L.	6	1/13	Milk‡		90	Slight	++	+++	Normal	++++	Italian
S.Q.	4	1/13		Moderate		+±	+++±	+++±	Porto Rican		
J.A.	5	1/13		Slight		+++	++++	Normal	Negro		
R.L.	5	1/19		Moderate		+++	Normal	Normal	Negro		
C.H.	20	1/25		Marked		+++	+++±	++++	Normal		Negro—1/25: calcium, 9.8 mg.; phosphorus, 3 mg. 2/23: calcium, 10.6 mg.; phosphorus, 5 mg.
K.S.	4	2/22		Slight		++	+++	Normal	Negro		
B.C.	7	3/2		Moderate		+			Porto Rican		
F.S.	15	3/17		Moderate		+	+±		Negro		
B.R.	6	3/17		Moderate		+±	+++		This infant had received 90 units of crystalline vitamin D in oil for one month, and no healing resulted		

two weeks later. Administration of 900 units of vitamin D in oil to ten rachitic infants resulted in beginning improvement within four weeks in all. One Negro baby, however, who had marked rickets, showed only slight to moderate healing by the end of 12 weeks. Lewis concluded that the 900 units in oil was a good therapeutic dose for mild or moderate cases of rickets, but might not be adequate for severe forms. He commented that the therapeutic results obtained from 90 units in milk were superior to those obtained with 900 units in oil.

Supplee *et al.*,¹³⁷ intrigued by the evidence that vitamin D in milk was a more effective anti-rachitic agent than vitamin D in oil, undertook an evaluation of the factors in milk that might have accounted for this enhancement effect. Using the rachitic rat assay technic, they found marked differences in the anti-rachitic response, depending on the vehicle in which the vitamin D had been delivered. Milk and even an isolated milk constituent, lactalbumin, were shown to have enhanced the potency of vitamin D. The combination of the lipid-free lactalbumin with the vitamin was found to have exhibited a greater anti-rachitic potential than the lactalbumin-vitamin in combination with lipids. They concluded that vitamin D administered in the water phase was more effective clinically than when administered in an oil vehicle.

Since vitamin D in milk is much more active than when it is administered in oil, the addition of 400 units to a quart of milk may be the equivalent of several times that quantity administered in oil. For the children with a high intake of milk, it can be presumed that the daily intake of vitamin D is undoubtedly higher. Were there no risk in providing therapeutic dosages of vitamin D to the entire population instead of prophylactic doses, this excess over that considered sufficient by the Committee on Nutrition of the American Pediatric Association (400 units from all sources)¹⁰⁴ could be safely disregarded. There is evidence, however, that infantile hypercalcemia, renal acidosis, and nephrocalcinosis may well be related to moderately high intakes of vitamin D by children with high susceptibility to this vitamin.

HISTOPATHOLOGIC FINDINGS IN ANIMALS WITH EVIDENCE OF VITAMIN D-TOXICITY: CORRELATION WITH CLINICAL SYNDROMES

It is clear from the foregoing that there is a wide range of response to vitamin D. A dose little more than that usually necessary to prevent rickets may produce severe toxicity in some children even though it is well tolerated by most. The lesions produced in such susceptible children are very similar to those produced in experimental animals by toxic doses of vitamin D.

Experimental Hypervitaminosis D

As early as 1927–1928, Pfannenstiel¹³⁸ and Kreitmair and Moll¹³⁹ reported pathological changes in animals given large doses of irradiated ergosterol. Kreitmair and Moll¹³⁹ described the pathological effects of 0.2 to 10.0 mg/day in mice, rats, guinea pigs, rabbits, cats, and dogs. Death ensued after six days to three months; postmortem changes included massive deposits of calcium in arteries, kidneys, heart, and other organs. In 1929 Harris and Moore¹⁴⁰ showed that the toxic effects are specifically attributable to the vitamin. Duguid¹⁴¹ observed, in 1930, that there was a considerable variation in susceptibility of their rats to 10 mg of irradiated ergosterol in olive oil fed for a maximum of 34 days. Of 120 rats fed the supplement for 25 days, only 71 showed aortic lesions, and 92 showed lesions in the kidneys. The earliest signs of vitamin D toxicity

TABLE 5

THE CALCIFICATION OF TISSUES
BY EXCESSIVE DOSES OF
IRRADIATED ERGOSTEROL

Calcium, mg per 100 g					
Tissue	Normal mean a	Ergosterolized mean b	$E_{\Delta} = \sqrt{a^2 + b^2}$ *	Δ/E_{Δ} †	Probability
Adrenal	37.6 ± 3.24	203.1 ± 81.9	81.9	2.02	0.04
Aorta	64.23 ± 6.84	175.3 ± 35.7	35.9	>3	<0.01
Brain	55.4 ± 14	125 ± 16.7	21.8	>3	<0.01
R. ventricle	2.27 ± 4.43	149.6 ± 37.69	37.9	2.9	<0.01
L. ventricle	18.3 ± 1.64	220.4 ± 63	64	>3	<0.01
Kidney	55.6 ± 15.9	671.6 ± 236.3	236.8	2.6	<0.01
Liver	17.9 ± 1.22	122.8 ± 45.1	45.5	2.33	0.02
Lung	88.6 ± 13.2	338.4 ± 160.2	165	1.514	0.13
Muscle	17.8 ± 1.16	64.8 ± 13.3	13.4	>3	<0.01
Skin	23.6 ± 1.95	69.8 ± 16.1	16.2	2.85	<0.01
Spleen	14.3 ± 2.19	100.8 ± 21.26	21.4	>3	<0.01
Thyroid	101.3 ± 22.9	509.3 ± 144.66	147	2.77	<0.01

Phosphorus, mg per 100 g					
Tissue	Normal mean a	Ergosterolized mean b	$E_{\Delta} = \sqrt{a^2 + b^2}$ *	Δ/E_{Δ} †	Probability
Adrenal	595.8 ± 30	648 ± 109.18	113.3	<1	0.64
Aorta	272.2 ± 18.4	315.4 ± 13.1	28.07	<1	0.12
Brain	1317.3 ± 31.5	1018.3 ± 130	164	1.82	0.07
R. ventricle	708.1 ± 37.7	736.9 ± 42.36	50.6	<1	0.61
L. ventricle	767.3 ± 50.3	694.5 ± 49.2	70.4	1.34	0.27
Kidney	815.8 ± 74.3	994 ± 126.5	146.7	1.21	0.23
Liver	790 ± 24	681.5 ± 104.1	106.8	1.02	0.30
Lung	865 ± 53.3	977.6 ± 163.6	172	<1	0.51
Muscle	699.3 ± 43.6	536.7 ± 47.7	60.4	2.19	0.03
Skin	152.3 ± 37.1	280 ± 50.5	62.5	2.05	0.04
Spleen	925.1 ± 40.8	901.3 ± 59.4	72.12	<1	0.74
Thyroid	554 ± 57	712.6 ± 119	132	1.2	0.23

* $E_{\Delta} = \sqrt{a^2 + b^2}$, a=standard deviation of normal series.

b=standard deviation of experimental series.

† Δ/E_{Δ}

Δ =difference between means of the two series

From Reed, C.I., E.A. Dillman, E.A. Thacker, & R.I. Klein. 1933. J. Nutr. 6: 374.

the size of the individual injections. There were wide variations in the amounts of vitamin D that were toxic, but there was a tendency towards a comparable degree of calcium deposition in most of the tissues of any given animal.

Because the arterial sclerosis produced by vitamin D in the experimental animals seemed to have involved primarily the media, whereas that seen in man was usually correlated with intimal damage associated with hypercholesterolemia, Harrison¹⁴⁸ studied the combined effect of sequentially administered cholesterol and vitamin D in rabbits. In those cases in which the vitamin D was given after challenge with cholesterol, medial sclerosis was produced in aortas that were already the seat of severe cholesterol sclerosis,

intimal thickening. Where there was distortion or disruption of the elastic fibers, and muscle cells were destroyed, there was calcium deposition. Two of the rabbits died in congestive heart failure; four others had focal myocardial lesions, consisting in three of periarterial muscle necrosis, a cellular reaction, and staining reaction suggesting calcium deposition. Ten of the rabbits given vitamin D had lesions immediately subjacent to the endocardium. Serum calcium levels higher than those of control animals were found in the experimental rabbits for 32-38 weeks after discontinuing administration of vitamin D.

It is worthy to note that in the series of experiments with rats reported by Gillman and Gilbert,¹⁴⁹ there was another similarity to the syndrome of infantile hypercalcemia, which includes failure to gain weight, atony, and muscle wasting. Toward the end of the five-day period, during which very high doses of vitamin D were given, there was a precipitous loss of weight, with obvious wasting, and severe frank degeneration of the skeletal muscles.

More recent work has emphasized the role of the mucopolysaccharides in the lesions caused by vitamin D.¹⁵⁰⁻¹⁵³ Eisenstein and Groff¹⁵⁰ reported that rats given massive doses of vitamin D₂ showed not only elevated serum calcium levels but also increases in seromuroid. The deposition of calcium in the soft tissues (renal tubular casts, in myocardium at the site of inflammation, and in the aorta), took place in a matrix composed at least partially of an unidentified polysaccharide. Gillman and Hathorn¹⁵¹ found that the initial aortic lesions (in rats) appeared six to 15 days after the first dose of calciferol, and were localized around the medial vascular elastic membranes just deep to the intima. Calcification occurred early and was associated with local accumulation of nonsulphated P.A.S.-positive polysaccharide. If the dose of vitamin D was not very high, the initial mineralization sometimes resolved in the next six to ten days, after which the tissue between the injured elastic membranes became laden with metachromatic mucopolysaccharide. In such instances, regeneration of the original vascular architecture took place. With more severe or prolonged injury, fibrosis and scar formation occurred, preceded by localized accumulation of metachromatic, sulphated mucopolysaccharides. In their later studies of the histochemical and chemical changes associated with the soft tissue calcification following acute intoxication with vitamin D, Gillman *et al.*¹⁵² identified the tissue polysaccharides. They, too, found a rise in serum mucopolysaccharides, which was prolonged for about two-thirds of the entire observation period of 160 days in contrast to the hypercalcemia, which persisted for only ten days. The levels of aortic hexose and hexosamine approximately doubled; these increases were not quantitatively related to the calcium content. The laying down of calcium was, however, closely paralleled by large increases in the phosphorus content of the aortas. The total aortic collagen appeared to have increased toward the end of the experimental period, coinciding with the histological appearance of aortic and coronary sclerosis. This group of investigators found that the serum mucoprotein changes of calciferol-intoxicated rats seemed to be more closely associated with necrosis and the subsequent healing process in the heart, kidney, and other soft tissues than with calcification.¹⁵³

Most recently, on the assumption that the supravalvular aortic stenotic lesion may result from intrauterine damage caused by administration of vitamin D to the pregnant mother,⁹⁹ Friedman and Roberts¹⁵⁴ studied the young of pregnant rabbits given 1.5-4.5 million units of vitamin D. Since all rabbits on 2.5-4.5 million units died within 65 days after their first injection, the results of the study pertain only to the rabbits given 1.5 million units. The blood levels of

myocardial infarction were found in two of the infants who survived the neonatal period; renal damage ranging from cloudy swelling of the parenchyma to marked calcification of the renal tubules was seen in two. Considering the possibility that hypervitaminosis D may be a causal factor in generalized arterial calcification of infancy, Stryker recorded the available information on vitamin D intake in his series of cases, as well as in the 15 cases he tabulated from the literature. In the case of the infant who died at three months, the family physician had suspected hypervitaminosis D but could elicit no history of unusual vitamin intake by either the mother or by the infant. It is of interest that the sibling of this infant was reported by the physician to have died with a similar clinical picture, but no autopsy had been done. The infant who died at seven months had been breast-fed, and had received two drops of a concentrated cod-liver oil twice daily during the first month. No history regarding vitamin D intake was obtained in the remaining three cases. Among the patients tabulated from the literature was one reported by Lightwood¹⁵⁶ of a child who died at 27 months. She had been found to have hypercalcemia (11 mg%) and albuminuria, and at autopsy showed fibrotic and calcified glomeruli, interstitial fibrosis and degeneration, fibrosis, and calcification of glomeruli and tubules. She had osteoporosis and osteosclerosis and was described as mentally retarded and dwarfed. Having been reported as having received only "physiological" amounts of vitamin D, at a time (1932) when there was no vitamin supplementation of food, this may be the first recorded case of infantile hypercalcemia caused by hyper-reactivity to vitamin D. Her mother had taken no vitamin D supplements during pregnancy. Among the remaining 14 infants, tabulated by Stryker, were two reported by Anderson and Schlesinger,¹⁵⁷ who had had moderate hypercalcemia and renal damage but who were reported to have had hyperparathyroidism; one of these two infants however, had received about four times the usual amount of vitamin D. All others had been given a single dose of 300,000 units. Menten and Fetterman¹⁵⁸ reported an infant who died of generalized arteriosclerosis and myocardial infarction, born to a mother who had taken no vitamin D during pregnancy, but who had taken two capsules of dicalcium phosphate daily. He had received five drops of oleum percomorph daily starting at two weeks. At one month he began to vomit; at 54 days he seemed cranky and upset—both symptoms that are now commonly considered characteristic of infantile hypercalcemia. At autopsy, all of the superficial coronary branches were found to be thickened, sclerotic and calcified, and the aorta was diffusely thickened. Histological examination revealed coarsening of the internal and medial elastica fibers of the coronaries, with calcification, and degeneration of elastic fibers of the media of the aorta, with calcareous thickening. Foci of myocardial infarction and fibrosis were present. Hyalinization of about 2% of the glomeruli was noted, as was calcific degeneration of occasional glomeruli and collecting tubules. The remaining two infants reported by Menten and Fetterman¹⁵⁸ were siblings, who died at six and seven weeks, respectively, and who showed generalized arteriosclerosis, myocardial infarction, and parenchymatous degeneration of the kidneys. The commonest change seen in the aorta was swelling and degeneration of irregularly distributed elastic fibers; there were also atheromatous thickenings, with thinning of the underlying media. The infant reported by Wilkerson⁹⁸ as having hypercalcemia of infancy, who had severe calcinosis of arteries, kidneys, and soft tissues on autopsy at 17 weeks, and who had never received more than 500 units daily of vitamin D, may also be grouped with the infants described above. Hunt and Leys,¹⁵⁹ who compared the pathological changes seen in two siblings who died at four weeks

that myocardial degeneration might be another facet of the syndrome. Perou⁵ also found evidence of myocardial fibrosis in one of his cases of supra-avalvular stenosis. If, indeed, these three conditions represent increasingly severe manifestations of excessive response to vitamin D, it is not surprising that in the form characterized by infantile arteriosclerosis, there is focal myocardial necrosis or infarction and calcification, as has been reported in acute vitamin D toxicity studies in rats^{145,149} and in rabbits.^{65,142} The less acute myocardial lesions seen in older infants bear a resemblance to the later lesions reported in rats.¹⁴⁹ The myocardial fibrosis and atrophy seen in the children or young adults coming to autopsy with the supra-avalvular aortic stenosis syndrome may possibly represent the final cardiac phase of the disease. It is not known whether overdosage with vitamin D may contribute to renal calcinosis and cardiovascular disease in later life.

The stigmata of the Williams' syndrome include supra-avalvular aortic stenosis, mental retardation and a characteristic facies. Children with this disease resemble survivors of hypercalcemia of infancy, a disease associated with hyper-reactivity to vitamin D. The pathologic lesions of infants with acute hypercalcemia seen at autopsy^{23,52,62,66,96,98} resemble those seen during the acute or subacute phase of experimental hypervitaminosis D in the laboratory,¹⁴¹⁻¹⁵⁴ and those reported in infants with generalized arteriosclerosis.^{131,132,155-160} Arterial changes include intimal and/or subintimal thickening, with fragmentation and degeneration of the internal elastic lamina, and medial degenerative changes, thickening, and metastatic calcification, particularly in the aorta. In the kidneys are seen glomerular ischemia, with endothelial proliferation, periglomerular fibrosis, reduction in numbers of tubules, flattened tubular epithelium, hyaline, granular, or calcareous casts, and calcium deposits in lining cells and in basement membranes. Survivors of the acute phase of the disease, who had the peculiar facies characteristic of the Williams' syndrome, and who exhibited cardiac damage, hypertension, and supra-avalvular stenosis, at autopsy^{7,24,34,78} were found to have had lesions that resembled the supra-avalvular aortic lesions reported by Perou in "congenital" aortic stenosis,⁵ and by Gillman and Gilbert¹⁴⁹ late in the course of vitamin D toxicity in rats. It is noteworthy that the aortic stenotic lesions described by Friedman and Roberts¹⁵⁴ in three-month-old rabbits, whose mothers had been given an enormous dose of vitamin D during gestation, were similar both to those reported by Perou⁵ and by others^{3,11,33} in clinical supra-avalvular stenosis and to the lesions in rats after loading with vitamin D.¹⁴⁹ The renal changes seen in such children either at autopsy or after biopsy included contracted, granular kidneys with numerous areas of calcification^{7,24,33,74,101} and were similar to those seen as a late expression of vitamin D toxicity in the experimental animal.^{141,144}

From the available evidence, it seems unlikely that the pathologic findings in these severe clinical syndromes, which are so similar to those produced experimentally by toxic doses of vitamin D, can be merely coincidental. Great variations in the responses to vitamin D in animals and in man have been recognized. It has long been accepted that Negro infants are unduly susceptible to rickets, and because of relative resistance to the anti-rachitic activity of vitamin D, often require higher prophylactic doses of vitamin D than do white infants, as well as much higher therapeutic doses. That at the other end of the spectrum are children (predominantly white) who need very little vitamin D, who are very susceptible to this vitamin, and who cannot tolerate even slightly elevated doses over minimal amounts, has not been realized. From the data reported in 1937 by Drake,¹²³ it appears that a significant number of children

vitamin D requirements are very low.

The possibility that the syndrome of infantile hypercalcemia may be caused by overdosage with vitamin D during pregnancy has been suggested.^{8,99,154} That vitamin D overdosage, especially to pregnant women who may be unduly susceptible to vitamin D, may cause fetal damage seems probable. Thus far, however, search through the literature for verified instances of overdosage with vitamin D during pregnancy of mothers of infants with the syndromes described in this paper has failed to reveal any such cases. In fact, a normal infant was born to a mother who had accidentally taken high daily doses of vitamin D for two weeks early in her gestation period.¹⁵⁵ Since she had an older child with the Williams syndrome, the failure of the vitamin load to cause infantile hypercalcemia is quite significant. Earlier reports of questioning of mothers of children with infantile hypercalcemia revealed that in the ten from whom data were obtained, there were intakes no higher than 1,000 units daily during their pregnancy.^{7,23,26,46,103,156} In generalized arteriosclerosis of infancy, resulting in death by two months of age, which would appear to be more likely to have been caused by prenatal insult, evidence that vitamin D had not been taken during pregnancy was given in two instances.^{132,158} Since infants are known to have immature enzyme systems, it seems more likely that administration of vitamin D during early infancy to hyper-reactive infants is the cause of these pediatric diseases than is its administration during pregnancy.

These observations raise the question: Just what are the best means of assuring optimum protection against rickets in children with high vitamin D requirements, without at the same time precipitating cardiovascular, renal, and possibly mental, disease in children with very much lower requirements, who may be hyper-susceptible to vitamin D? In the case of a substance to which there is such a wide variation in response, the amount unavoidably taken by those on a recommended diet should not exceed that found to be anti-rachitic in the group most susceptible to the action of vitamin D. The larger requirements of children more susceptible to rickets should be provided by specific supplements. Whether there should be addition of vitamin D to foods, including milk, should be reconsidered. The demonstrated increased potency of vitamin D in milk and the variability in the amount ingested make it difficult to guard against ingestion of doses that are potentially harmful.

SUMMARY

1. The striking histopathological similarity of several serious diseases of infancy and childhood that are characterized by cardiovascular, renal, and brain damage, to the changes seen in experimental vitamin D toxicity, points to vitamin D as an important etiological factor in these diseases.

2. There is strong evidence that hypercalcemia of infancy is caused by hyper-reactivity to vitamin D, as indicated by (a) the increased incidence of the disease in England during a period of overdosage with vitamin D; (b) its occurrence in infants given massive doses of vitamin D; (c) demonstration of increased anti-rachitic activity of the blood of affected infants; and (d) metabolic evidence of increased response to vitamin D by such infants.

3. Supravalvular aortic stenosis, mental retardation, and characteristic facies constitute a syndrome that is strikingly similar to that seen in survivors of hypercalcemia of infancy, and to that which has been reported in children given massive doses of vitamin D during infancy and early childhood.

15. WOOLEY, C.R., D.M. HOSIER, C.V. MECKSTROTH, H.D. SIRAK & W. MOLNAR. 1963. Supravalvular aortic stenosis: an emerging clinical entity. *Circulation* 28: 827.
16. MOTSCH, K., J. BARTEL, S. IWANOFF & W. PROSTMANN. 1963. Das syndrom der supravalvularen aortenstenose. *Cardiologia* 43: 379.
17. TREDE, MM. & F. LINDER. 1962. Die supravalvulare aortenstenose. *Chirurgia* 33:155.
18. MYERS, A.R. & P.W. WILLIS. 1966. Clinical spectrum of supravalvular aortic stenosis. *Arch. Int. Med.* 118:553.
19. EBERLE, P. & A.J. BEUREN. 1963. Chromosome studies in patients with supravalvular aortic stenosis. *Lancet* II: 438.
20. MERRITT, A.D., C.G. PALMER, P.R. LURIE & E.L. PETRY. 1963. Supravalvular aortic stenosis: genetic and clinical studies. *J. Lab. Clin. Med.* 62(6): 995.
21. KURLANDER, G.J., E.L. PETRY, H. TAYBI, P.R. LURIE & J.A. CAMPBELL. 1966. Supravalvular aortic stenosis. Roentgen analysis of twenty-seven cases. *Amer. J. Roentgen.* 98: 782.
22. SCHLESINGER, B., N. BUTLER & J. BLACK. 1952 Londoner Fall. *Helv. Paediat. Acta* 7:335.
23. SCHLESINGER, B.E., N.R. BUTLER & J.A. BLACK. 1965. Severe type of infantile hypercalcemia. *Brit. Med. J.* 127.
24. BLACK, J.A., N.R. BUTLER, and B.E. SCHLESINGER. 1965. Aortic stenosis and hypercalcaemia. *Lancet* II:546.
25. GARCIA, R.E., W.F. FRIEDMAN, M.M. KABACK & R.D. ROWE. 1964. Idiopathic hypercalcemia and supravalvular aortic stenosis. *New Eng. J. Med.* 271(3):117.
26. FRASER, D., B.S.L. KIDD, S.W. KOOK & L.A. PAUNIER. 1966. A new look at infantile hypercalcemia. *Pediat. Clin. N.A.* 13:503.
27. BAUMAN, A & C.G. BAUMAN. 1965. Idiopathic hypercalcemia of infancy simulating congenital heart disease. *N.Y. State J. Med.* 65(14): 1910.
28. BEUREN, A.J., C. SCHULZE, P. EBERLE, D. HARMJANZ & J. APITZ. 1964. The syndrome of supravalvular aortic stenosis, peripheral pulmonary stenosis, mental retardation and similar facial appearance. *Am. J. Cardiol.* 13:471.
29. BEUREN, A.J., J. APITZ & J. STOERMER. 1966. Vitamin D-Hypercalcemic Cardiovascular Disease. V. World Congress of Cardiology in New Dehli, India.
30. BEUREN, A.J., J. APITZ, J. STOERMER, B. KAISER, H. SCHLANGE, W. BERG & G. JAERGENSEN. 1966. Vitamin D-hypercalcemic cardiovascular disease. *Mscr. Kinderh.* 114: 457. (Ger.)
31. ANTIA, A.U., R.D. ROWE, O.E. OTTESEN, S. LEVIN & R.E. COOKE. 1965. Pathogenesis of the supravalvular aortic stenosis syndrome in children (abstract). *Circulation* 32: 44.
32. OTTESEN, O.E., A.U. ANTIA & R.D. ROWE. 1966. Peripheral vascular anomalies associated with the supravalvular aortic stenosis syndrome. *Radiol.* 86(3): 430.
33. PRIEST, J.H., & D.M. LANG. 1965. Aortic stenosis and hypercalcaemia. *Lancet* I:1335.
34. BONHAM-CARTER, R.E.B., & J. SUTCLIFFE. 1964. A syndrome of multiplearterial stenosis, in association with the severe form of idiopathic hypercalcaemia. *Arch. Diseases Childhood.* 39:418.
35. FRIEDMAN, W.F. 1965. Supravalvular aortic stenosis (Re: C. Farrehi's Report). *Amer. J. Disease Children.* 109: 261.
36. TAUSSIG, H.B. 1965. On the evolution of our knowledge of congenital malformations of the heart. *Circulation* 31:768.
37. UNSIGNED EDITORIAL. 1966. Supravalvular aortic stenosis. *JAMA* 198(2):1302.
38. BLACK, J.A. 1964. Idiopathic hypercalcemia and vitamin D. *German Medical Monthly (English Language Ed.)* 9(7): 290.
39. LIGHTWOOD, R. 1952. Idiopathic hypercalcemia with failure to thrive. *Proc. Roy. Soc. Med.* 45:401.
40. FANCONI, G. & P. GIRARDET. 1952. Chronische Hypercalcaemie, kombiniert mit Osteosklerose, Hyperazotamie, Minderwuchs und kongenitalen Mibbildungen. *Helv. Paediat. Acta.* 7:314.
41. MITCHELL, R.G. 1960. The prognosis of idiopathic hypercalcemia of infants. *Arch. Diseases Childhood* 35:383.
42. SCHWARTZ, W.B. 1957. Discussion, Clinical Pathological Conference. The Children's Medical Center, Boston, Mass. *J. Pediat.* 51:461.
43. BONHAM-CARTER, R.E.B., C.E. DENT, D.I. FOWLER & C.M. HARPER. 1955. Calcium metabolism in idiopathic hypercalcaemia of infancy with failure to thrive. *Arch. Diseases Childhood* 30:399.
44. ZEFFREN, J.L. & H.O. HEINEMANN. 1962. Reversible defect in renal concentrating

- Dundee. *Lancet* 1:679.
77. FORFAR, J.O., S.L. TOMPSETT & W. FORSHALL. 1959. Biochemical studies in idiopathic hypercalcemia of infancy. *Arch. Diseases Children* 34:525.
 78. BARR, D.G.D. & D.M. DOUGLAS. 1965. Aortic stenosis and hypercalcemia. *Lancet* 2:1126.
 79. CREERY, R.D.G. & D.W. NEILL. 1955. Intake of vitamin D in infancy. *Lancet* 269:372.
 80. CREERY, R.D.G. & D.W. NEILL. 1954. Artificial feeding of infants. *Lancet* 2:1124.
 81. WOODCOCK, R.H. 1954. Letter to the Editor. *Lancet* 267:244.
 82. BALL, W.A. 1954. Vitamin D and hypercalcemia in infants. *Lancet* 267:243.
 83. REPORT OF SUBCOMMITTEE, BRIT. PAEDIATRIC ASSOC. 1956. Hypercalcemia in infants. *Lancet* 271:136.
 84. JEANS, P.C. & G. STEARNS. 1938. The effect of vitamin D on linear growth in infancy. *J. Pediat.* 13:730.
 85. SHELDON, W., C. HARRIS, N. MORRIS & H. MACKAY. 1943. The dosage of vitamin D. *Arch. Diseases Childhood* 18:58.
 86. UNSIGNED EDITORIAL. 1956. Infantile hypercalcemia. *Brit. Med. J.* 1:159.
 87. HUBBLE, D. 1956. Hypercalcemia in infancy. *Lancet* 143:
 88. REPORT OF THE JOINT SUBCOMMITTEE ON WELFARE FOODS. Ministry of Health, Dept. of Health for Scotland. Central and Scottish Health Services Councils Standing Medical Advisory Committees. London, Her Majesty's Stationery Office, 1957.
 89. BING, F.C. 1941. Vitamin D milk containing 600 U.S.P. units of Vitamin D to the quart is not eligible for list of accepted foods. *J. Am. Med. Assoc.* 116:413.
 90. FELLERS, F.X. 1958. "Vitamin D activity" in idiopathic hypercalcemia. *Am. J. Diseases Children* 96:476.
 91. FELLERS, F.S. & R. SCHWARTZ. 1958. Etiology of the severe form of idiopathic hypercalcemia of infancy. A defect in vitamin D metabolism. *New Eng. J. Med.* 259:1050.
 92. DAESCHNER, G.L. & C.W. DAESCHNER. 1957. Severe idiopathic hypercalcemia of infancy. *Pediat.* 19:362.
 93. SHIERS, J.A., E.B.D. NEUHAUSER & J.R. BOWMAN. 1957. Idiopathic hypercalcemia. *Am. J. Roentgen. Radium Therapy Nuclear Med.* 78:19.
 94. SINGLETON, E.B. 1957. The radiographic features of severe idiopathic hypercalcemia of infancy. *Radiol.* 68:721.
 95. BONGIOVANNI, A.M., W.R. EBERLEIN & I.T. JONES. 1957. Idiopathic hypercalcemia of infancy, with failure to thrive. *New Eng. J. Med.* 257(20): 951.
 96. RASHKIND, W.J., R. GOLINKO & M. ARCASOY. 1964. Cardiac findings in idiopathic hypercalcemia of infancy. *J. Pediat.* 58(4):390.
 97. MICHAEL, A.F., R. HONG & C.D. WEST. 1962. Hypercalcemia in infancy. *Am. J. Diseases Children* 104(3):235.
 98. WILKERSON, J.A. 1964. Idiopathic infantile hypercalcemia with subcutaneous fat necrosis. *Amer. J. Clin. Path.* 41(4):390.
 99. UNSIGNED. 1965. Idiopathic hypercalcemia of infancy. A review, The National Vitamin Foundation Inc. XI(2):Section eleven, 1.
 100. THOMAS, W.C., JR., H.G. MORGAN, T.B. CONNOR, L. HADDOCK, C.E. BILLS & J.E. HOWARD. 1959. Studies of antirickettic activity in sera from patients with disorders of calcium metabolism and preliminary observations on mode of transport of vitamin D in human serum. *J. Clin. Invest.* 38(7):1078.
 101. JUE, K.J., G.R. NOREN, & R.C. ANDERSON. 1965. The syndrome of idiopathic hypercalcemia of infancy with associated congenital heart disease. *J. Pediat.* 67:1130.
 102. GRIBETZ, D. & B.S. WOLF. 1959. Idiopathic hypercalcemia. *Am. J. Med.* 126:936.
 103. WILTSE, H.E., R.B. GOLDBLOOM, A.U. ANTIA, O.E. OTTESEN, R.D. ROWE & R.E. COOKE. 1966. Infantile hypercalcemia in twins. *New Eng. J. Med.* 275:1157.
 104. COMMITTEE ON NUTRITION, AM. ACAD. OF PEDIATRICS. 1963. The prophylactic requirement and the toxicity of vitamin D. *Pediat.* 31(3):512.
 105. MANIOS, S.G. & I. ANTENER. 1966. A study of vitamin D metabolism in idiopathic hypercalcemia of infancy. *Acta Paediat. Scandinav.* 55:600.
 106. GRUNDEER, E. 1955. Zur Vitamin D Uberdosierung im sauglingsund Kleinkindesalter. *Deut. Med. Wochschr.* 80:285.
 107. ROYER, P. & A. FREDERICH. 1960. Le rein de l'hypervitaminose D et des hypercalcémies idiopathiques chez l'enfant. *Path. Biol.* 8: 783.
 108. LEFEBVRE, G. 1959. En cherchant l'hypervitaminose D 2 et l'hypercalcémie idiopathique: un syndrome tres voisin. *Pédiatrie* 14:576.

139. KREITMAIR, H. & T. MOLL. 1928. Hypervitaminose durch grosse Dosen Vitamin D. *Munch. Med. Woch.* 37:637.
140. HARRIS, L., & T. MOORE. 1929. The specificity of vitamin D in irradiated ergosterol poisoning. The pathology of hypervitaminosis D. *J. Biochem.* 23:261.
141. DUGUID, J.B. 1930. Vitamin D sclerosis in the rat's aorta. *J. Path. Bact.* 33:697.
142. VANDERVEER, H.L. 1931. Hypervitaminosis D and arteriosclerosis. *Arch. Path.* 12:941.
143. SPIES, T.G. 1932. Production of nonfatal vascular sclerosis in rabbits by means of viosterol (irradiated ergosterol). *Arch. Int. Med.* 50:443.
144. SPIES, J.D. & E.C. GLOVER. 1930. Renal lesions with retention of nitrogenous products produced by massive doses of irradiated ergosterol. *Am. J. Path.* 6:485.
145. HAM, A.W. 1932. Mechanism of calcification in the heart and aorta in hypervitaminosis D. *A.M.A. Arch. Path.* 14:612.
146. STECK, I.E., H. DEUTSCH, C.I. REED & H.C. STRUCK. 1937. Further studies on intoxication with vitamin D. *Ann. Int. Med.* 10:951.
147. REED, C.I., E.A. DILLMAN, E.A. THACKER & R.I. KLEIN. 1933. The calcification of tissues by excessive doses of irradiated ergosterol. *J. Nutr.* 6:371.
148. HARRISON, C.V. 1933. Experimental arterial disease produced by cholesterol and vitamin D. *J. Path. Bact.* 36:447.
149. GILLMAN, J. & C. GILBERT. 1956. Calcium, phosphorus and vitamin D as factors regulating the integrity of the cardiovascular system. *Exp. Med. Surg.* 14:136.
150. EISENSTEIN, R. & W.A. GROFF. 1957. Experimental hypervitaminosis D: hypercalcemia hypermucoproteinemia and metastatic calcification. *Proc. Soc. Exper. Biol. & Med.* 94:441.
151. GILLMAN, T. & M. HATHORN. 1957. Pathogenesis of arterial sclerosis in the light of modern views on vascular microanatomy and the role of polysaccharides in wound healing. *J. Mt. Sinai Hosp. N.Y.* 24:857.
152. GILLMAN, T., R.A. GRANT & M. HATHORN. 1960. Histochemical and chemical studies of calciferol-induced vascular injuries. *Brit. J. Exp. Biol.* 41(1):1.
153. GRANT, R.A., T. GILLMAN & M. HATHORN. 1963. Prolonged chemical and histochemical changes associated with widespread calcification of soft tissues following brief acute calciferol intoxication. *Brit. J. Exper. Path.* 64(2):220.
154. FRIEDMAN, W.F. & W.C. ROBERTS. 1966. Vitamin D and the supravalvular aortic stenosis syndrome. The transplacental effects of vitamin D on the aorta of the rabbit. *Circulation* 34:77.
155. FORBES, G.B., C. CAFARELLI & J. MANNING. 1968. Vitamin D and infantile hypercalcemia. *Pediat.* 42(1):203.
156. LIGHTWOOD, R. 1932. A case of dwarfism and calcinosis with widespread arterial degeneration. *Arch. Diseases Childhood* 7:193.
157. ANDERSON, D.H. & E.R. SCHLESINGER. 1942. Renal hyperparathyroidism with calcification of the arteries in infancy. *Am. J. Diseases Children* 63:102.
158. MENTEN, M.L. & G.H. FETTERMAN. 1948. Coronary sclerosis in infancy. *Am. J. Clin. Path.* 18:805.
159. HUNT, A.C. & D.G. LEYS. 1957. Generalized arterial calcification of infancy. *Brit. Med. J.* 1:385.
160. TRAISMAN, H.S., N.M. LIMPERIS & A. TRAISMAN. 1956. Myocardial infarction due to calcification of the arteries in an infant. *A.M.A. J. Diseases Children* 91(1):34.